

膺復科臨床病例報告二

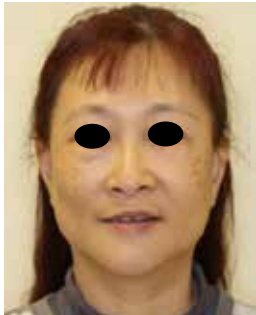學歷：台北醫學大學牙醫學系學士
現職：衛福部雙和醫院第五年住院醫師

時間：中華民國一〇三年九月

報告者：董芝廷醫師

指導：曹源利醫師

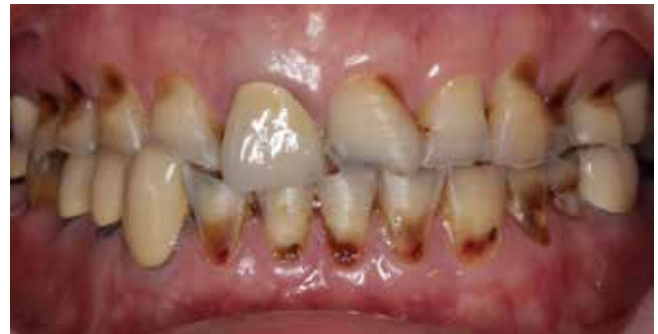General information



Name：曹雪 X
Birthday：53.12.19
Age：50 y/o
Gender：Female
Personality：philosophic
Occupation：家管

Chief complaints

- 希望擁有漂亮整齊潔白的牙齒
- 全口牙齒一吹到風就會酸
- 吃東西有時會咬到左臉頰



Medical history

- ▶ NPC s/p RT 20 years ago
 - follow up every 6 months at 亞東醫院
- ▶ Gastroesophageal reflux disease

Dental history

- ▶ Restorative history
- ▶ Endodontic history

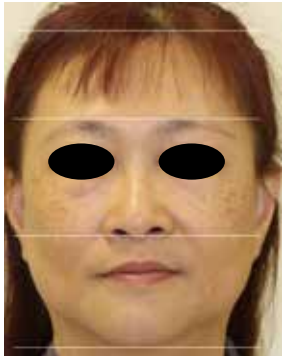Personal habits

- ▶ Smoking(-)
- ▶ Alcohol drinking(-)
- ▶ Betel nuts chewing(-) Clenching (-)
- ▶ Bruxism (?)
- ▶ Oral hygiene: fair

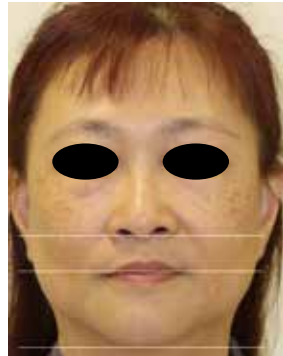Findings in masticatory system

- ▶ Muscle palpation pain (-)
- ▶ TMJ signs and symptoms (-)
- ▶ Clicking or crepitus (-)
- ▶ Mandible deviation or locking (-)
- ▶ Maximum mouth opening: 43mm

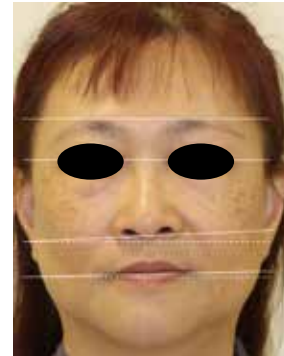Extraoral examination



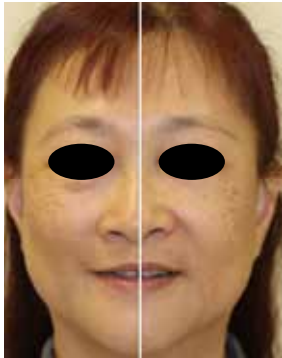▶ Facial proportion 0.8: 1: 1



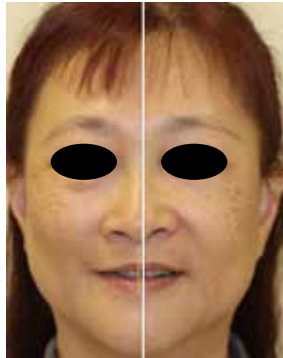▶ Lower third face 1: 2



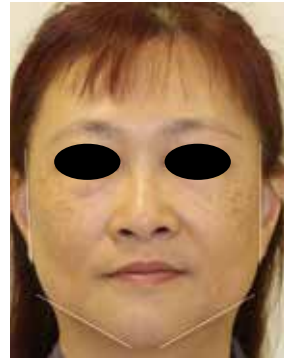▶ Horizontal reference line
interpupillary line



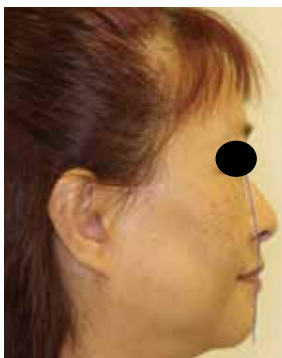
▶ Vertical reference line
facial midline
asymmetry



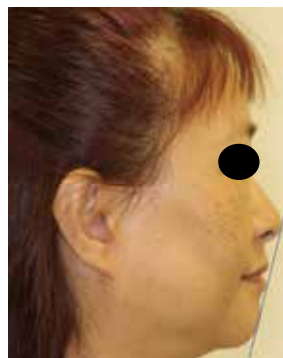▶ Midline
dental midline/ facial
midline: not coincidence



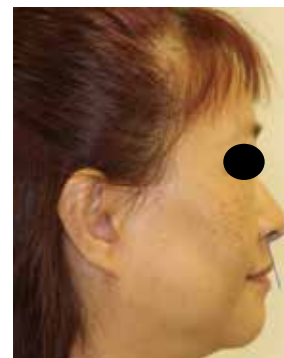
▶ Face form
square-tapering



▶ Profile
straight (170°)

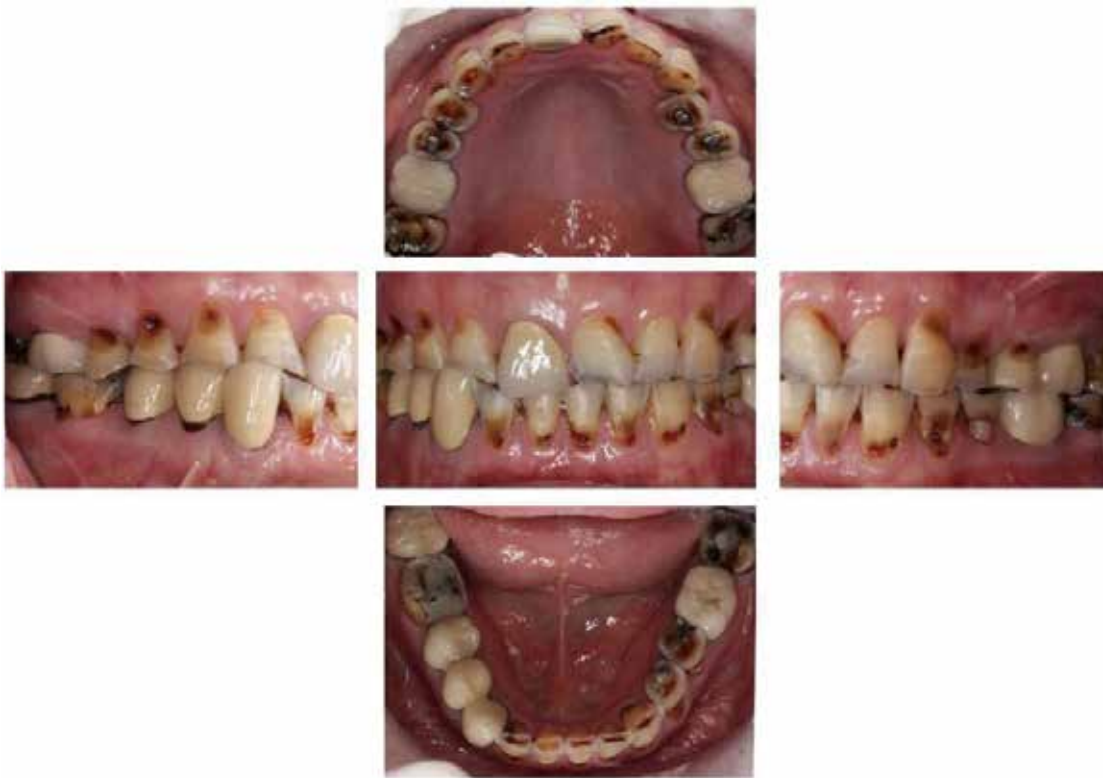

▶ E-line
upper lip -2mm
lower lip 0mm

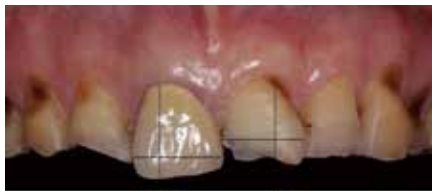

▶ Nasolabial angle
100° (100~ 105°)

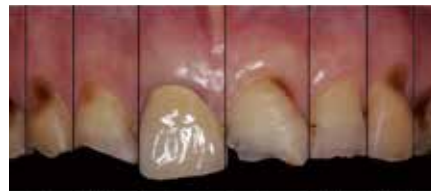Intraoral examination



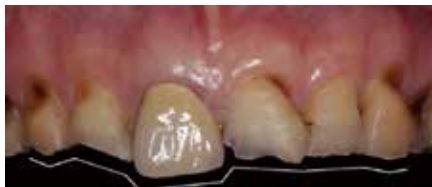Esthetic examination



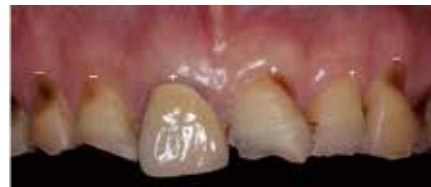Proportion of central incis



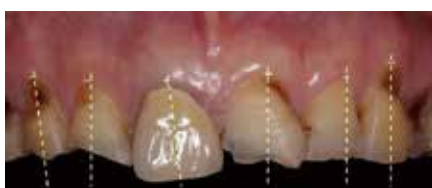Tooth-to-tooth proportion



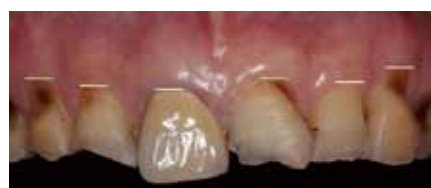Incisal curvatur



Zenith



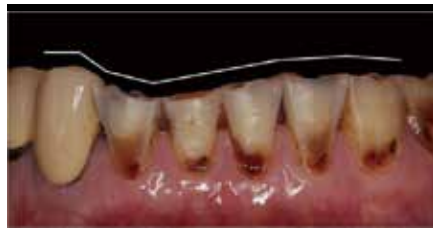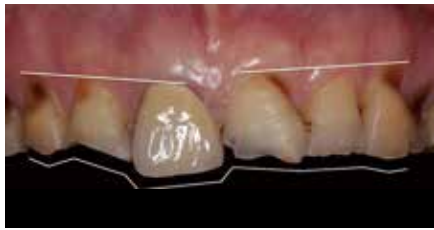Tooth axis



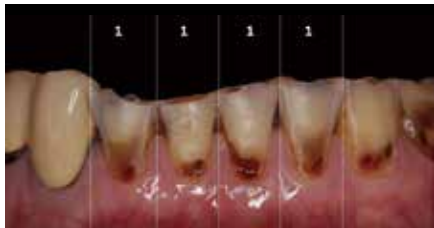
Gingival leve



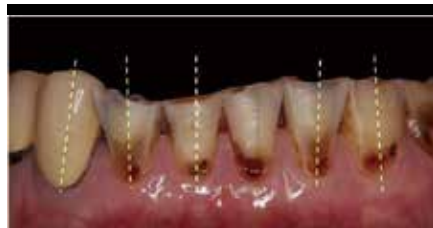病例讨论专栏



Incisal curvat



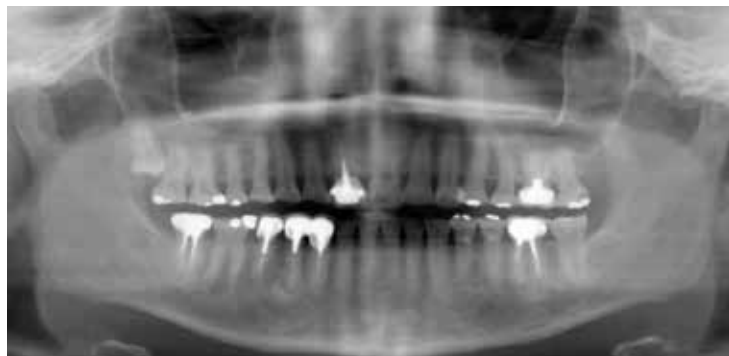
Tooth-to-tooth proportion



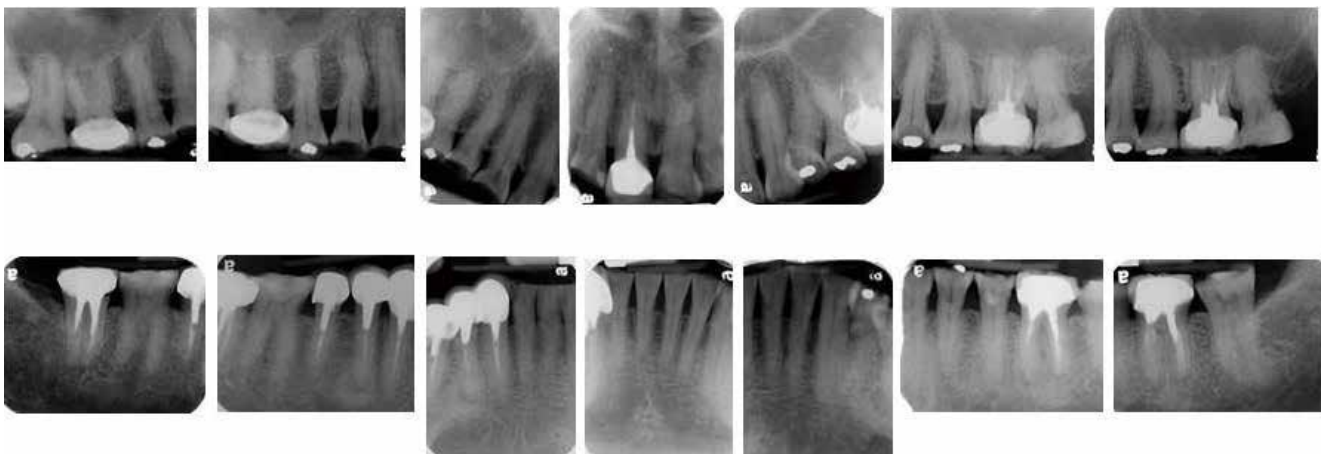
Tooth axi

Radiographic examination & Periodontal examination

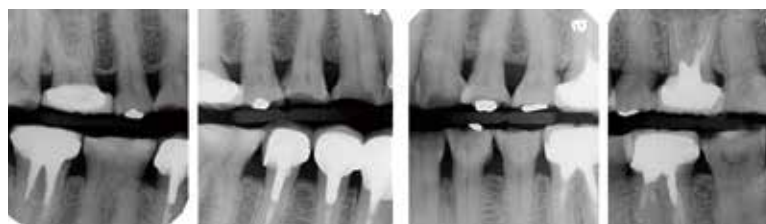Panoramic film



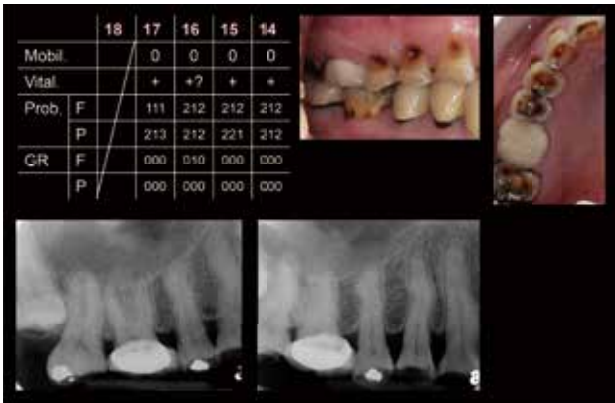Periapical film



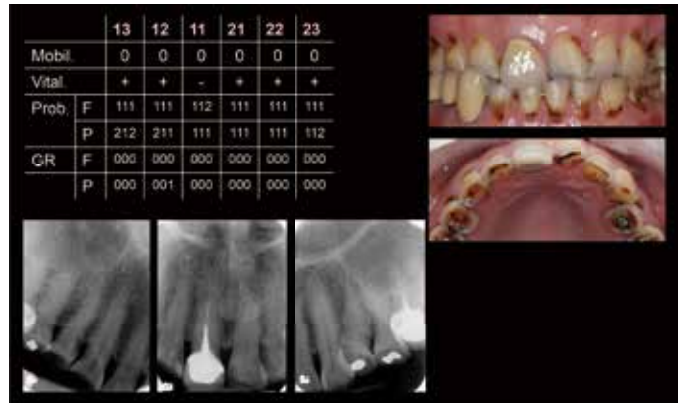Bitewing film



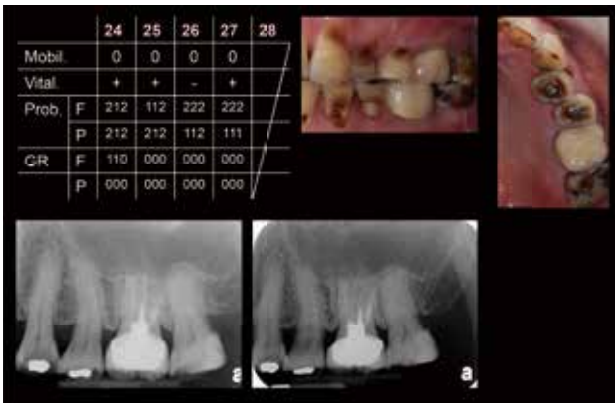UR area



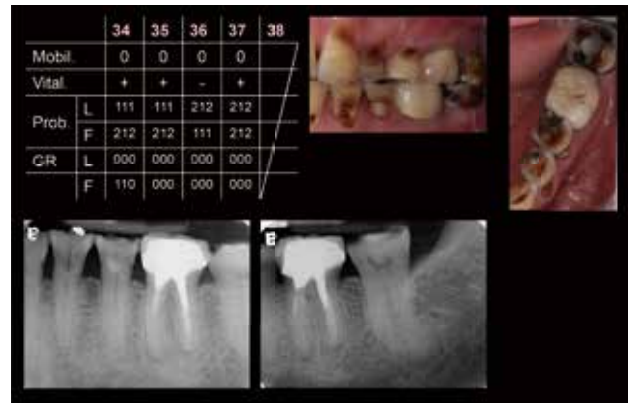LA area



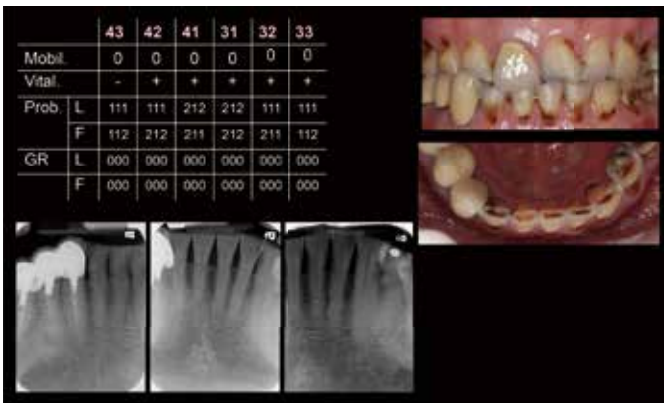UL area



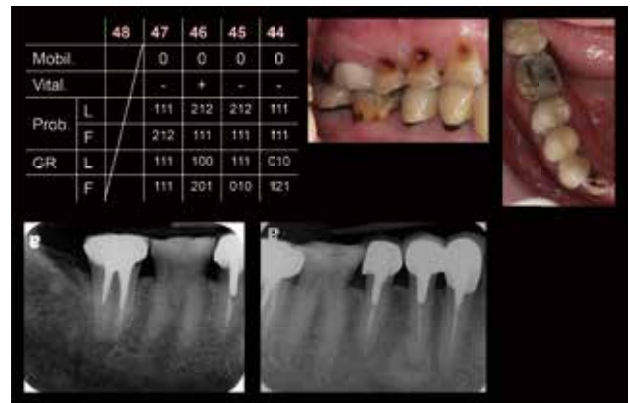LL area



LA area



LR area



Plaque Index

41%, O'Leary

		17	16	15	14	13	12	11	21	22	23	24	25	26	27
F		101	001	110	010	100	100	000	000	000	001	101	100	000	001
P		100	001	100	000	000	101	000	000	101	000	001	000	101	111

		47	46	45	44	43	42	41	31	32	33	34	35	36	37
L		110	011	101	100	100	100	000	000	001	010	101	100	101	111
F		101	101	101	110	101	101	001	100	001	101	100	101	101	111

Problem list

► Systemic

Sequela of radiation therapy

- Xerostomia
- Caries
- Osteoradionecrosis

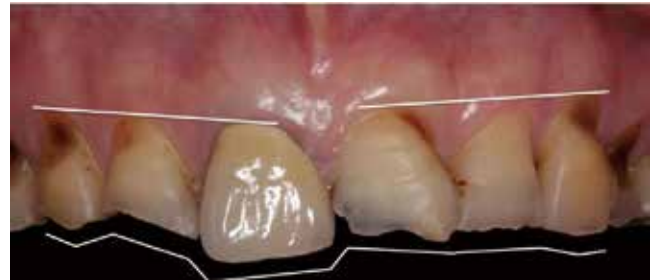► Gastroesophageal reflux disease

- Erosion
- Attrition

- Dentin sensitivity (14,15,24,25,27,31,32,33,34,35,37,41,42)
- Lack of overjet at posterior teeth (16,46,26,36)
- Apical lesion (26,36,44)
- Incomplete endodontic treatment (26,36,43,45,47)
- Overhang of FPD (16,45)
- Open margin of FPD (47)

► Esthetics

- Discoloration
- Incisal curvature irregularity
- Gingival level asymmetry
- Central incisor asymmetry
- Tooth W-L proportion



Diagnosis

- Caries
- Erosion
- Attrition
- Previously endodontic treated
- Asymptomatic apical periodontitis
- Xerostomia

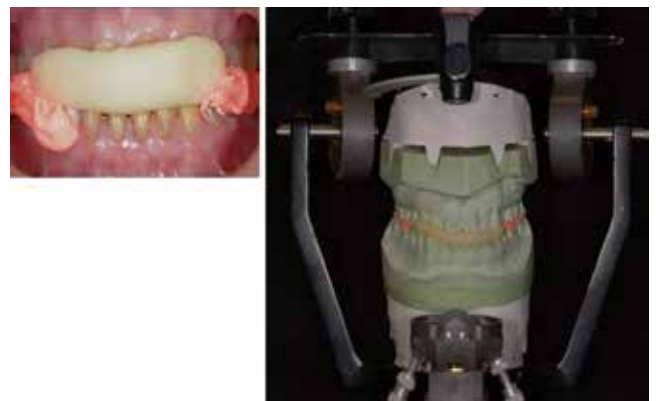Tentative treatment plan

1. Oral hygiene reinforcement
2. Caries restoration
3. Daily Fluoride application (1.23%NaF)
4. Evaluate the vertical dimension
5. Evaluate the abutment of FPD

Study cast mounting




CR/MI coincidence check




Study cast evaluation

Clinical crown height

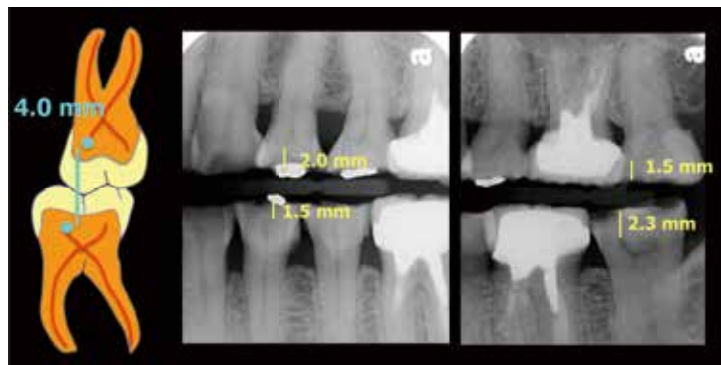


Occlusal space

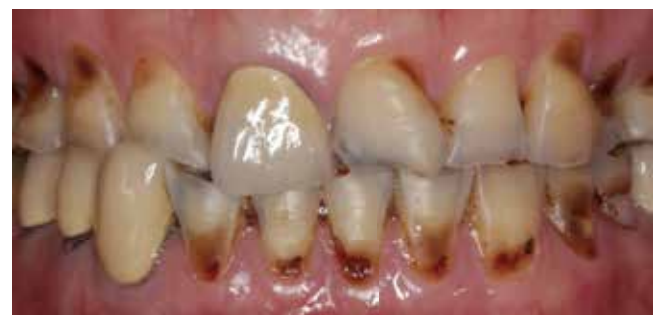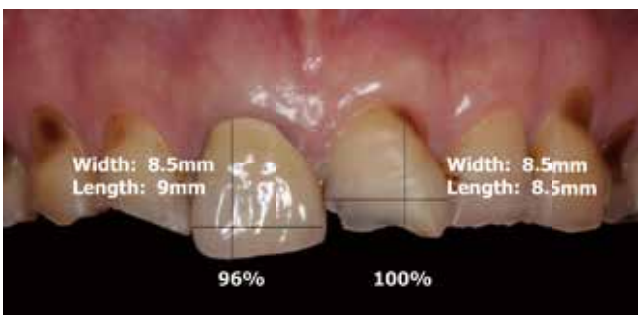


Radiographic evaluation

Dentin thickness



Study cast evaluation



Overjet 0mm overbite 0mm

- Space for restorations
- Minimal pulp invasion
- Esthetics

↓

Increase VD

- Freeway space – 4mm Pleasure, J Am Dent Assoc, 1951
- "s" sound – 4mm Pound, J Am Dent Assoc, 1977

↓

VD +2mm at incisor

Evaluation of vertical dimension

Definite treatment plan

Patient's expectation

1. 我想要跟林志玲一樣的潔白整齊牙齒。
2. 不喜歡金屬。
3. 不想要每顆牙都抽神經。
4. 不要切牙肉。

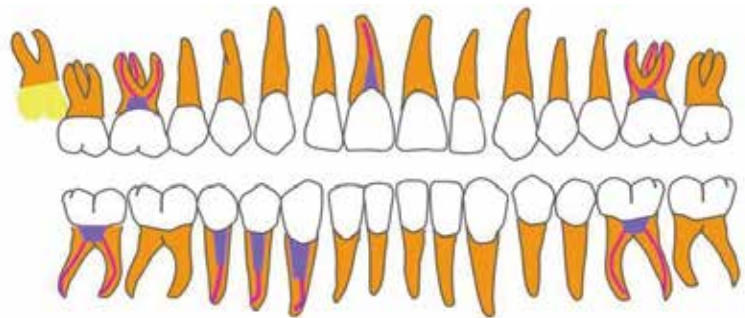
Esthetic goal

1. Bright and white tooth shade
2. Convex incisal curvature
3. Improved W-L proportion of tooth
4. Zenith, gingival level
-- non-surgical treatment

Definite treatment plan

Full mouth FPD

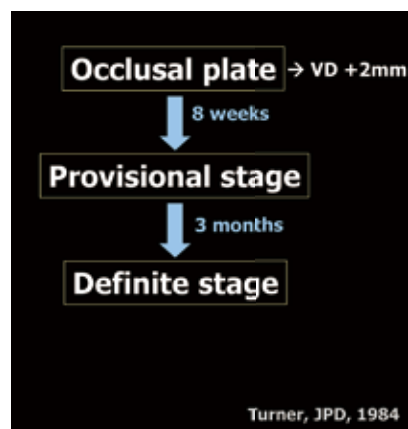
- ▶ increase VD 2mm at incisor
- ▶ prosthetic material
 - Anterior teeth: Lithium disilicate
 - Posterior teeth: Zirconia



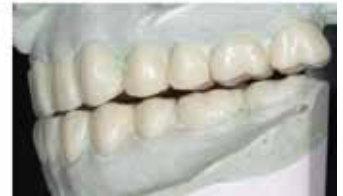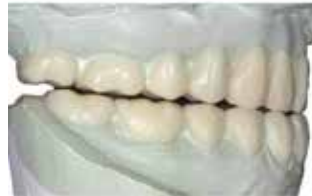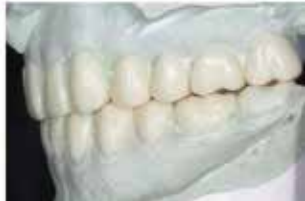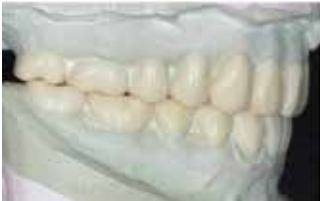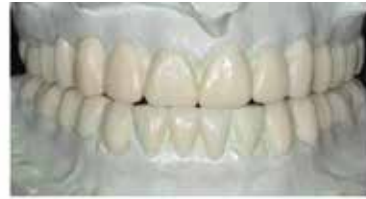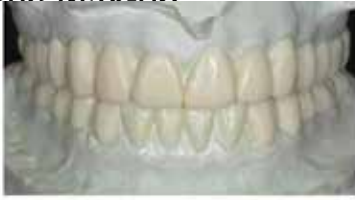Maintenance plan

- √ Food instruction
- √ Night guard
- √ Daily fluoride gel application
- ▶ 3 months
 - √ Oral hygiene
 - √ Check caries
 - √ Check occlusion
 - √ Check porcelain chipping
- ▶ 6 months
 - √ Check radiographic film FM scaling

Treatment sequence

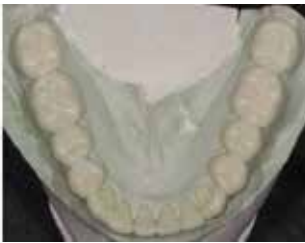
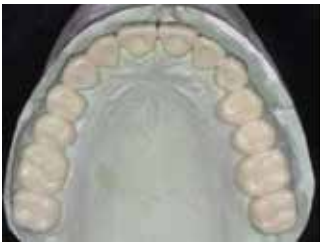
Diagnostic wax-up

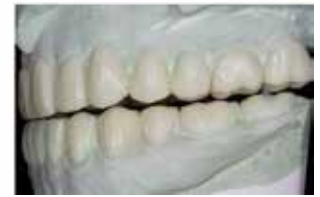
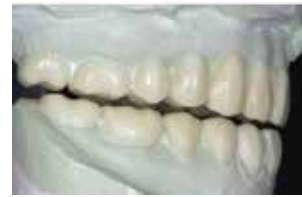
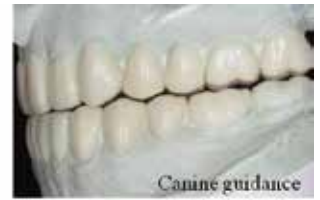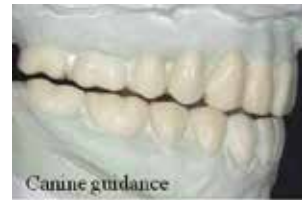MI

protrude

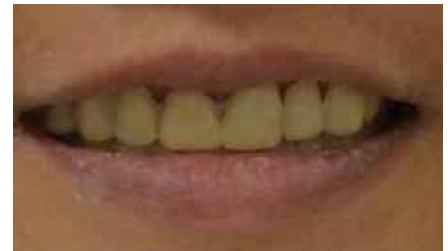
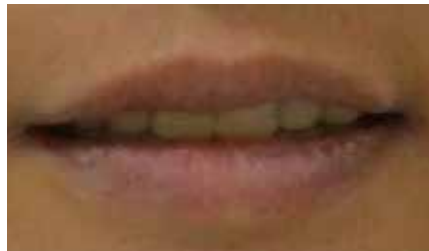
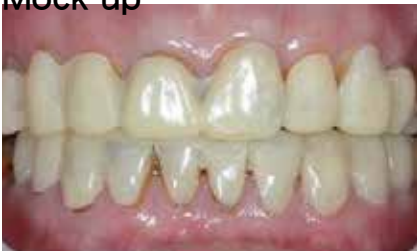Working side

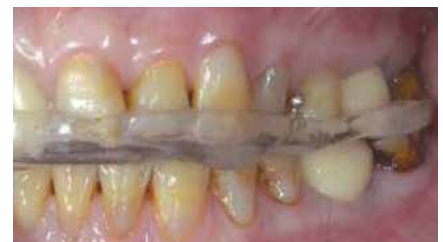
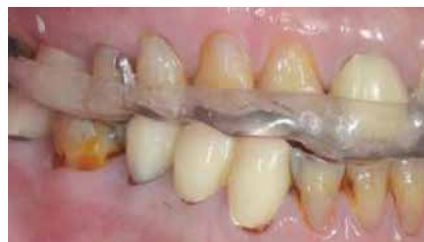
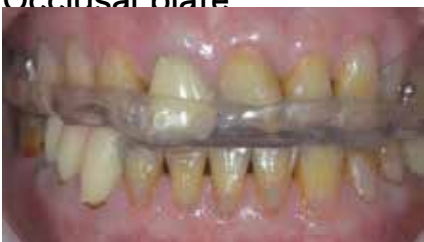Balancing side

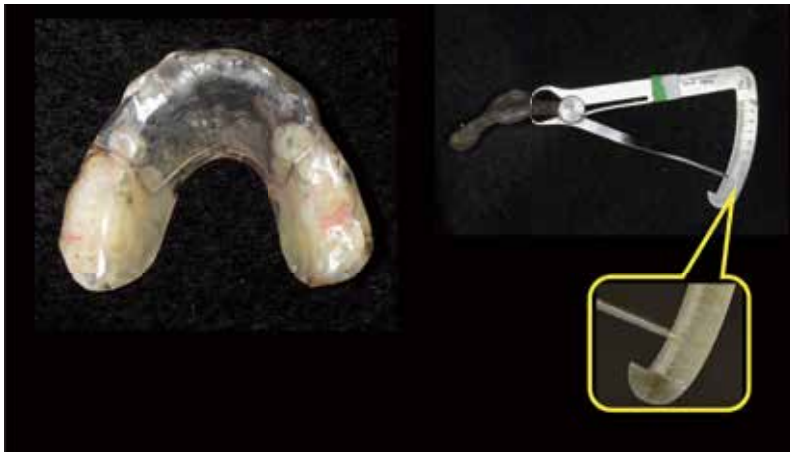Mock-up



Occlusal plate



病例讨论专栏



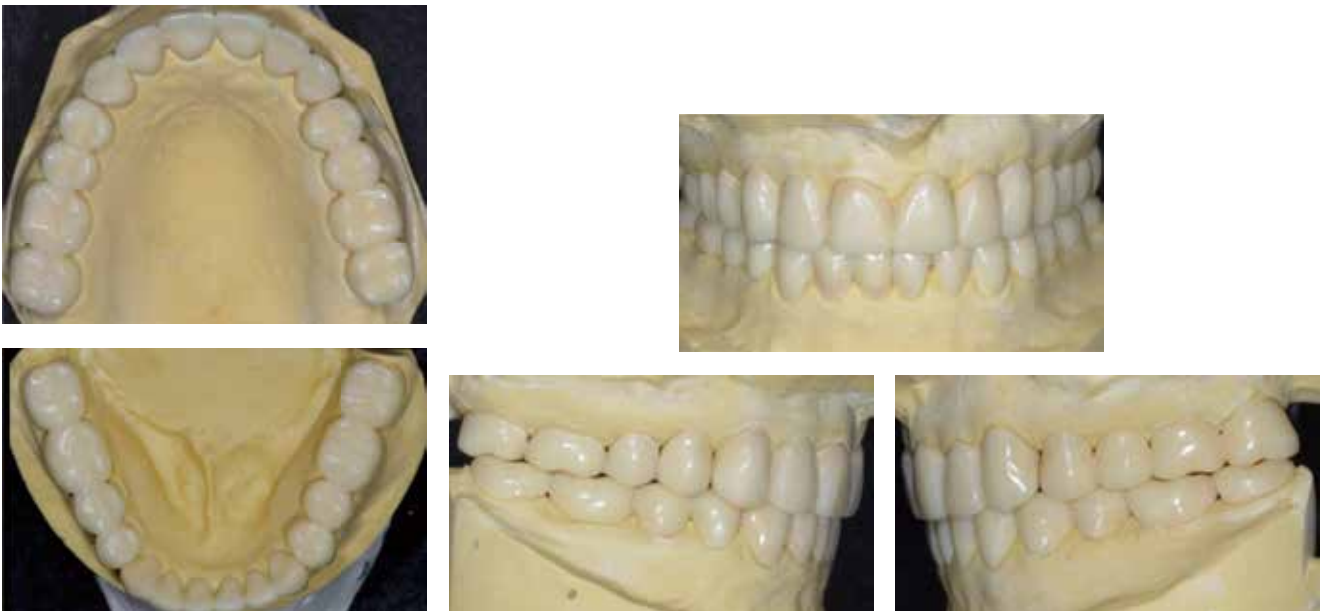Within 8 weeks..

- Tooth mobility (-)
- Bone resorption (-)
- Muscle/joint fatigue(-)
- Myofacial pain(-)
- Clenching(-)

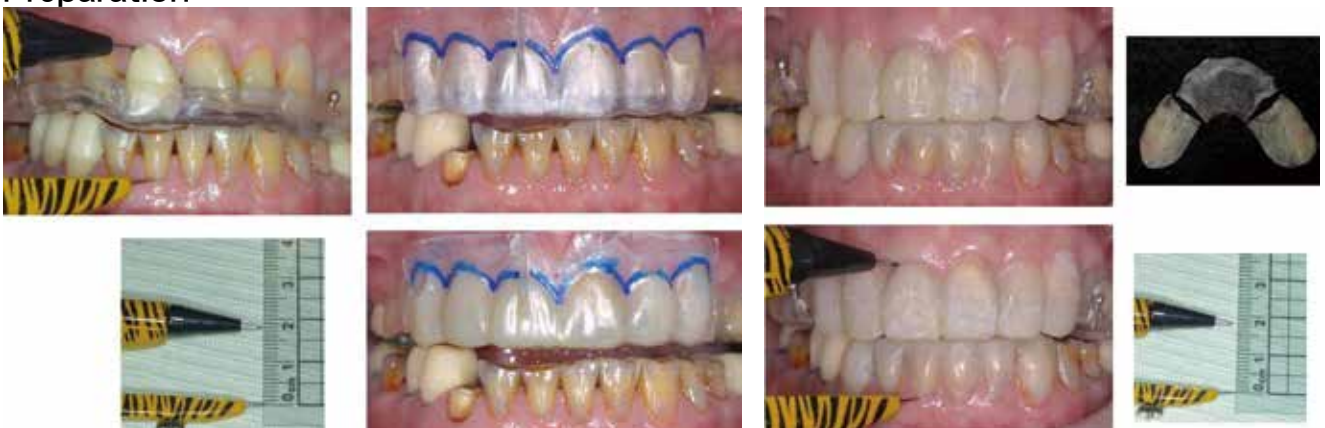Rivera-Morales, JPD, 1991

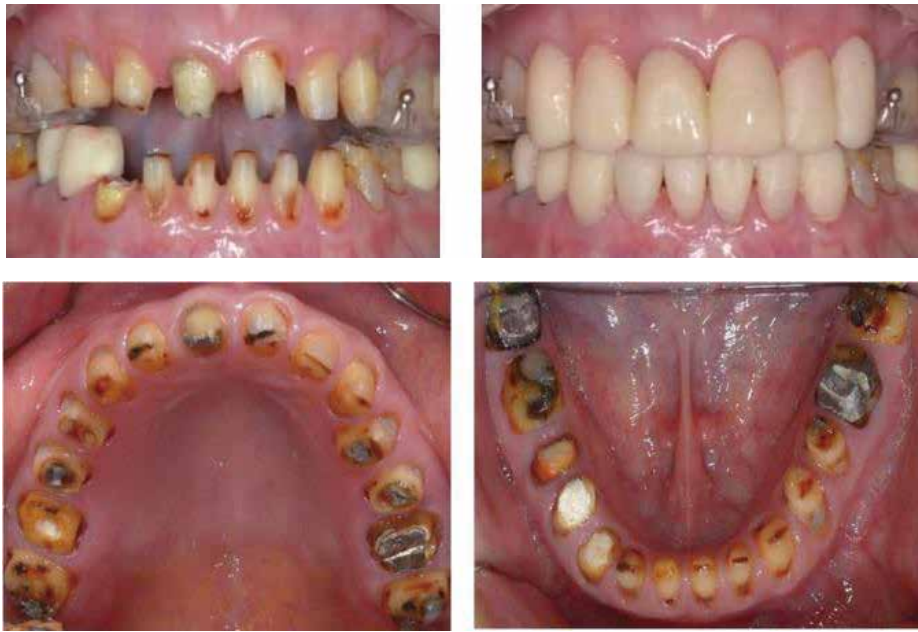Provisional stage

Provisional

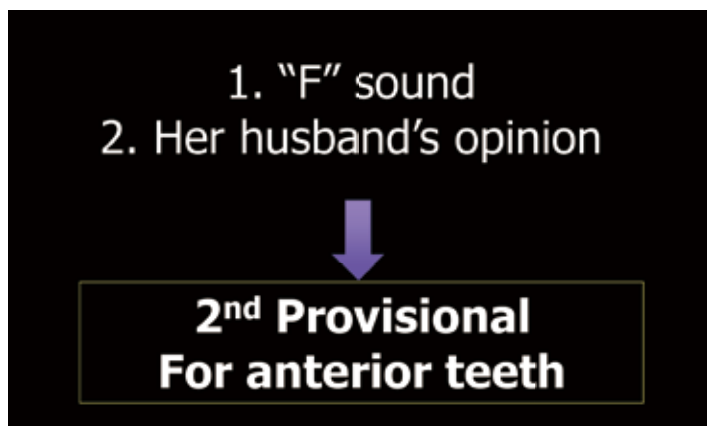
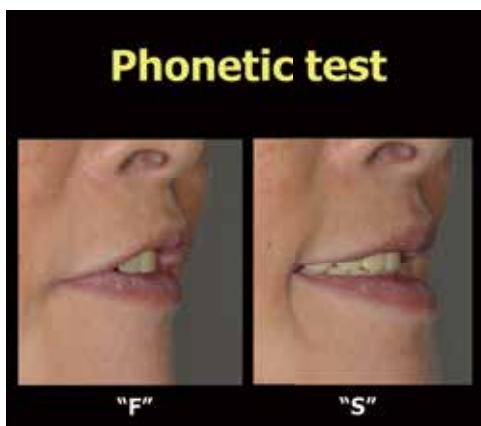
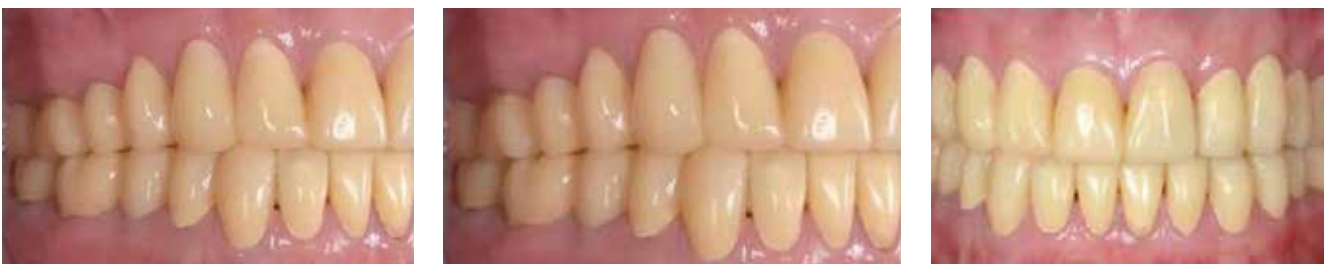
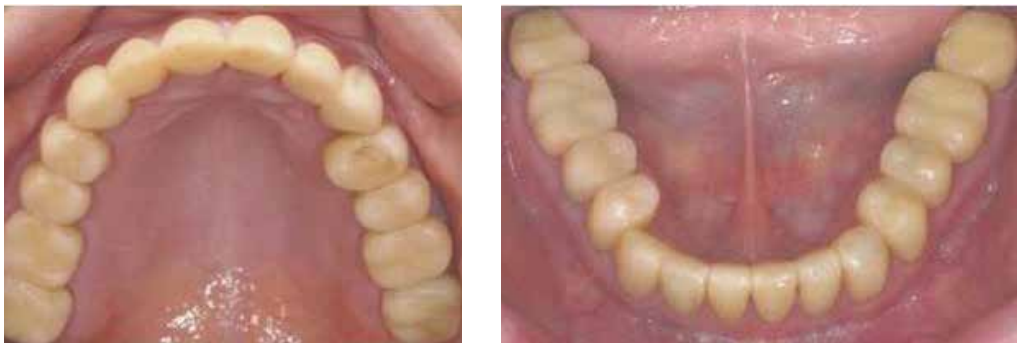
Preparation





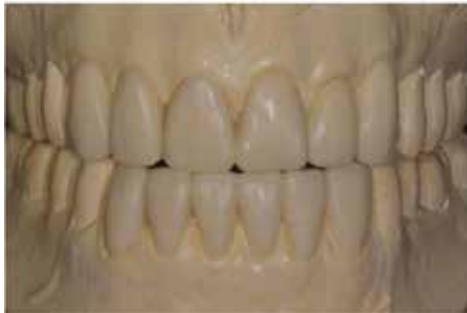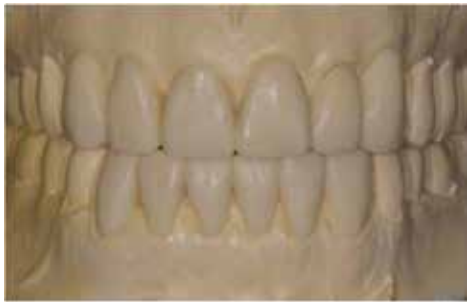Provisional restoration



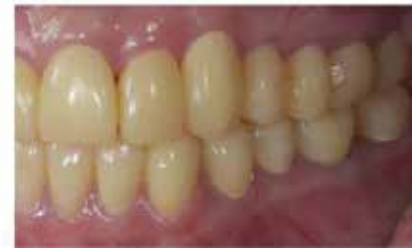
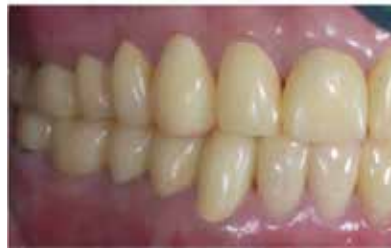
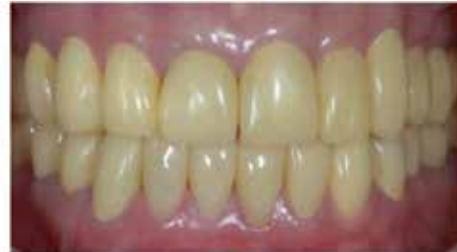病例讨论专栏

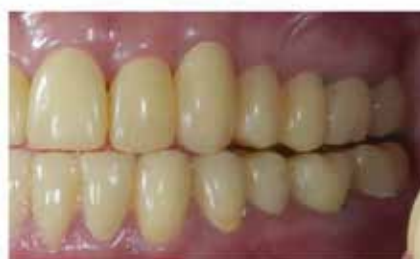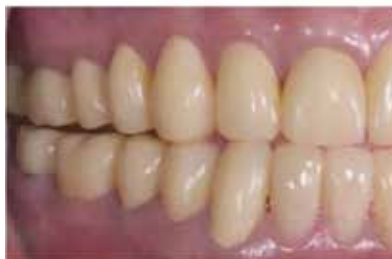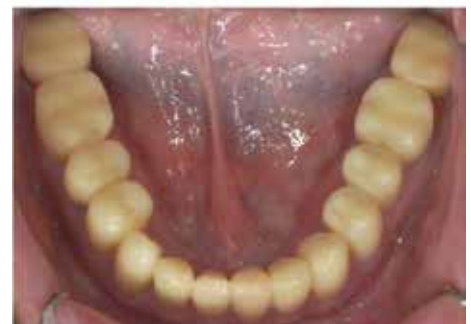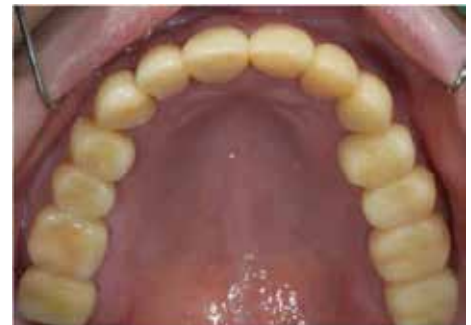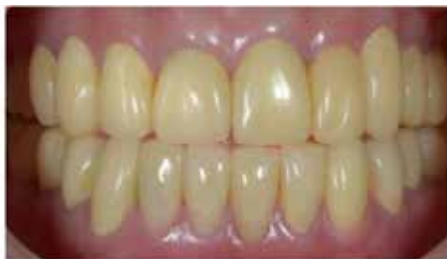2nd wax-up



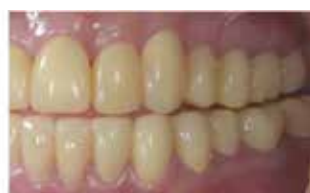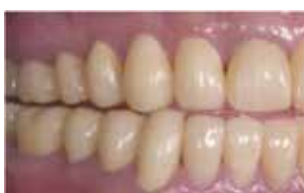Diagnostic wax-up



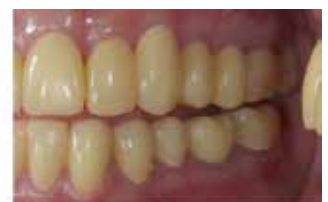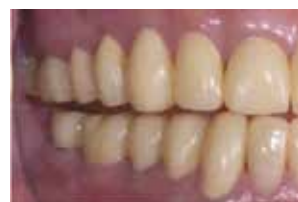MI



protrude



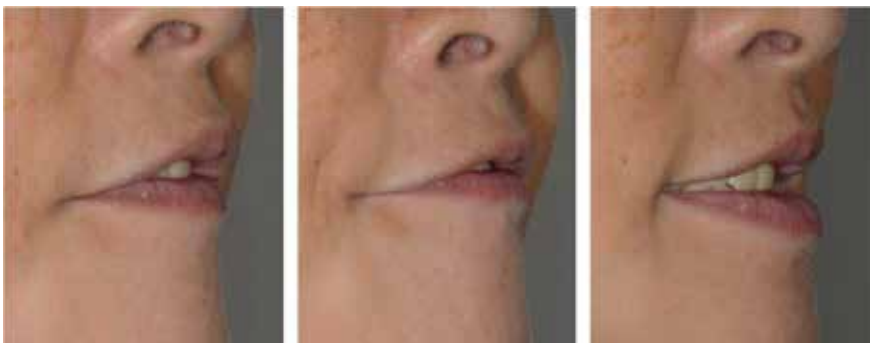
working side



balancing side



Phonetic test



"F"

"V"

"S"

CR/MI coincidence check



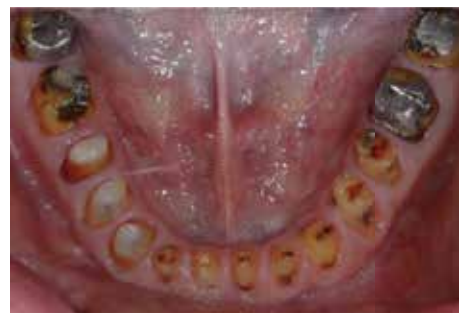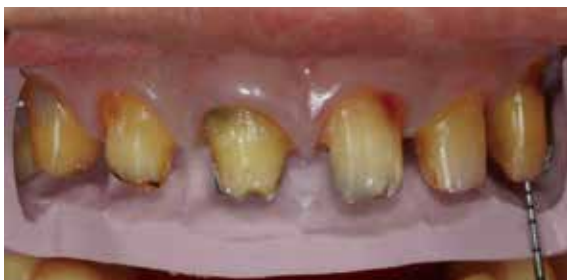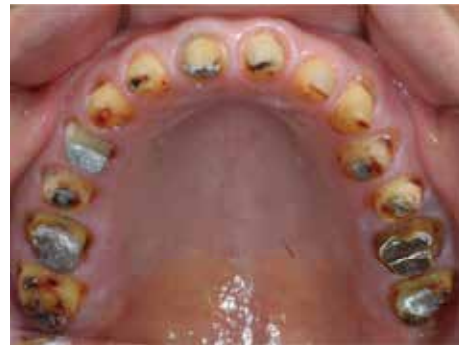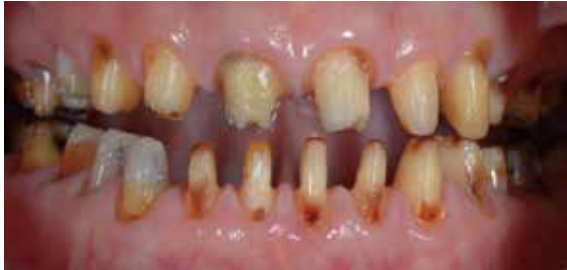Endodontic treatment

Tooth 16,14,27,37
biting pain and spontaneous pain

↓

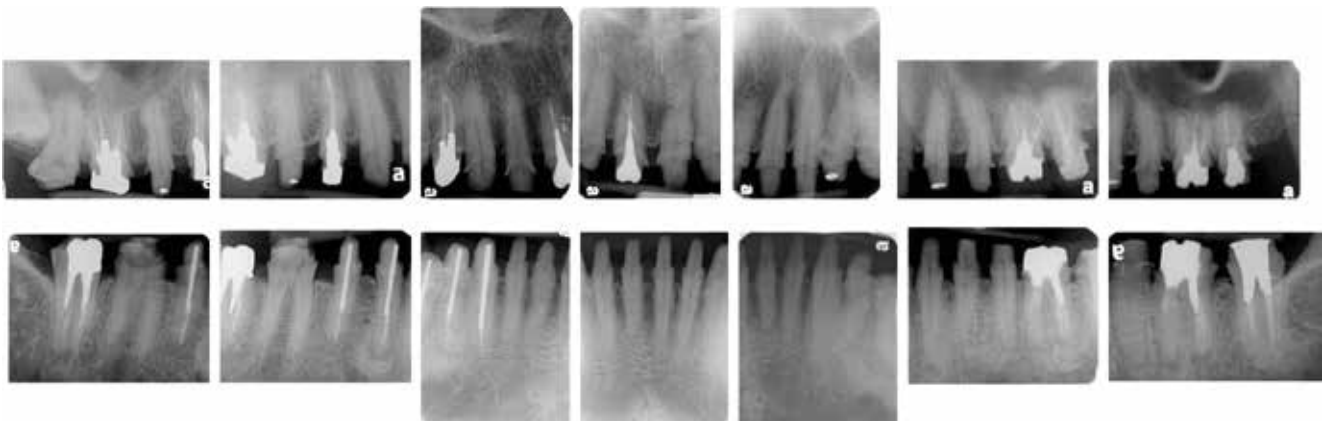
Endodontic treatment

Post and core deliver Final preparation

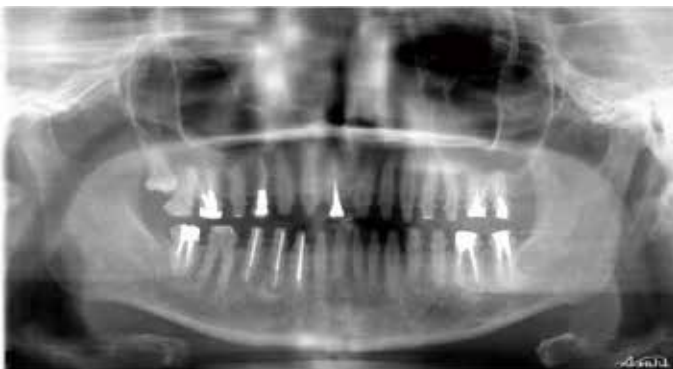

X-ray examination

Periapical film



Panoramic film



Follow up for 3 months..

Clench test
 Grinding test
 Fremitus
 Phonetic test
 Stability test
 Cement wash-out (-)

Bloom, Br Dent J, 2006

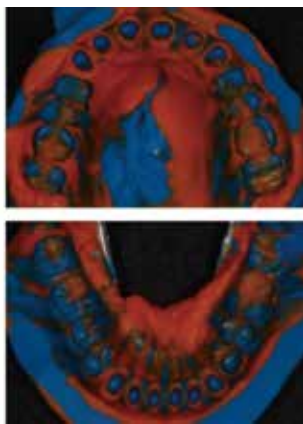
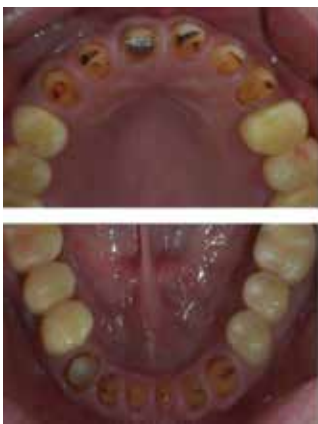Definite stage

Definite restoration -- Anterior teeth

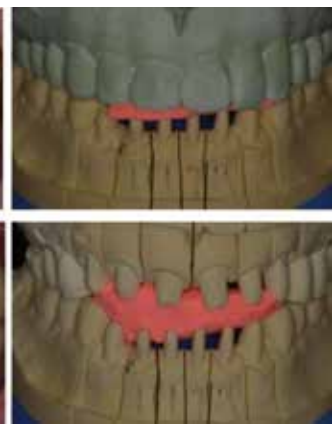
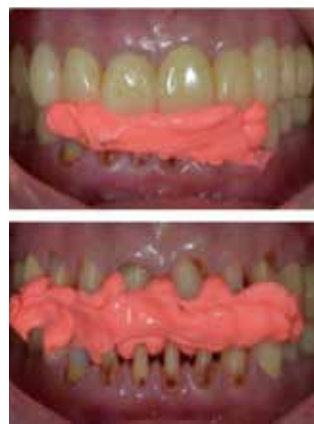Facebow transfer



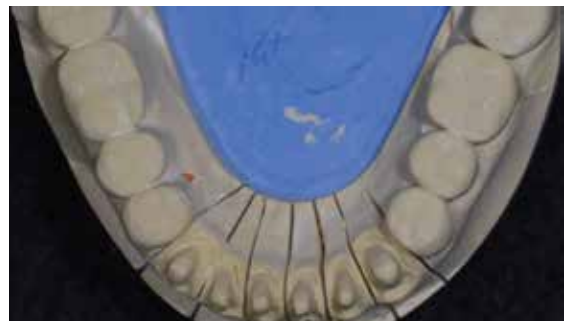
Impression



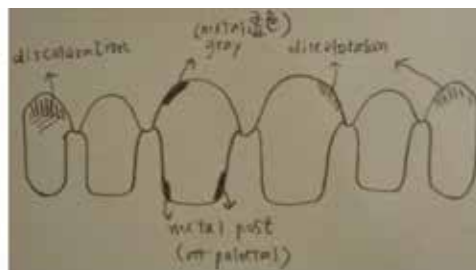
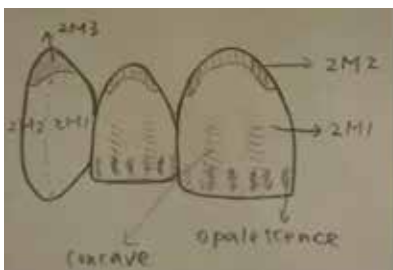
Bite and cross mounting



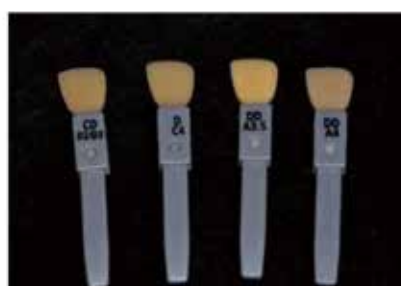Master cast



Shade



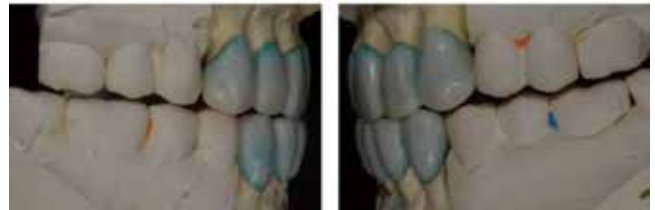
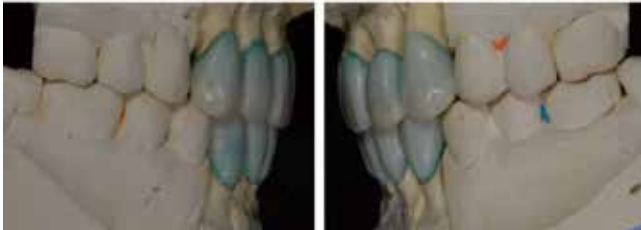
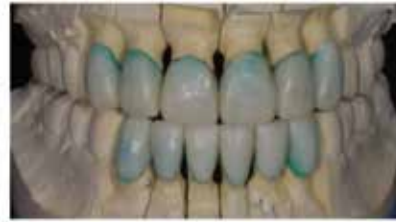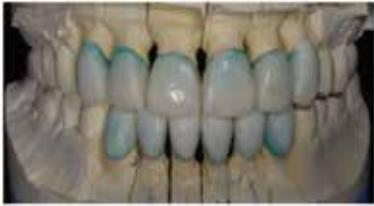Shade
1,2—2M1
3—2M1/2M2
4—7—2M2





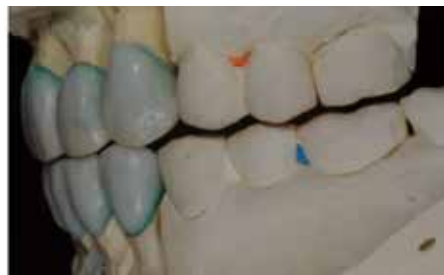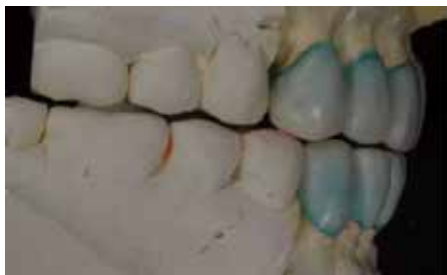病例討論專欄

Full contour wax up



MI

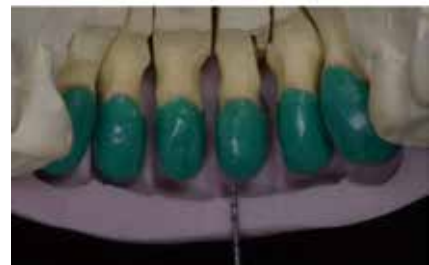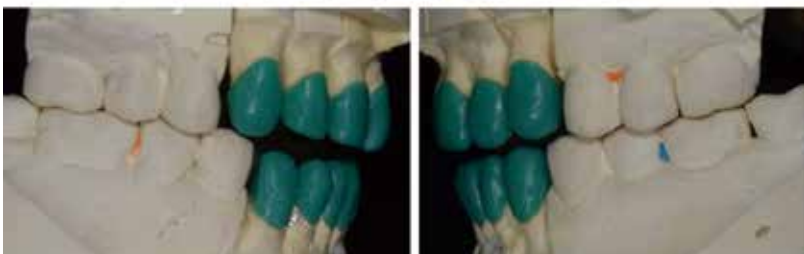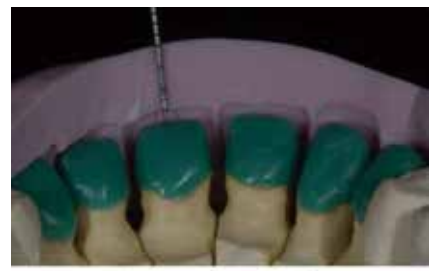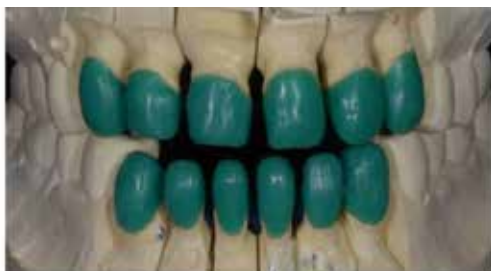protrude



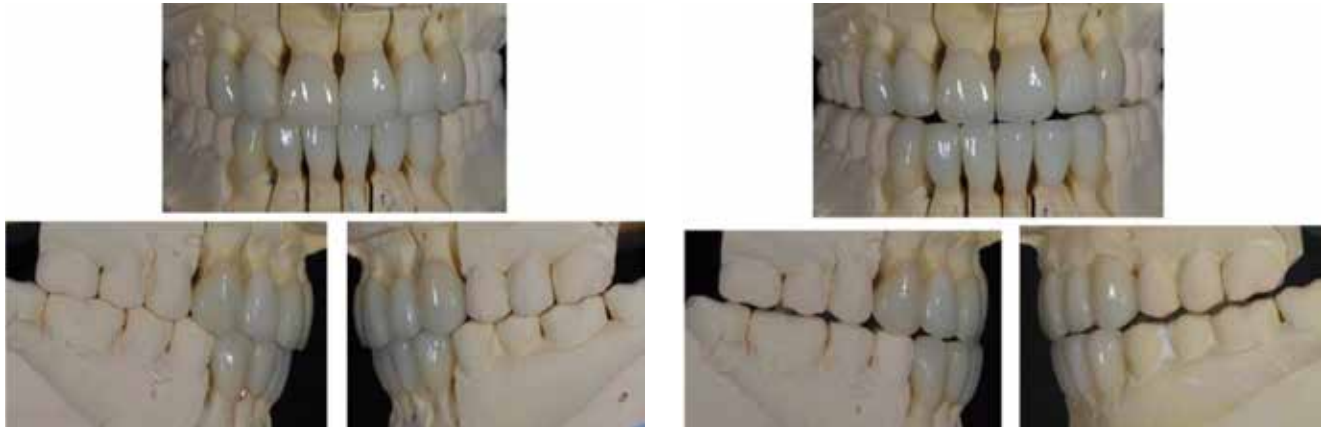
Working

Cut back

Check porcelain space

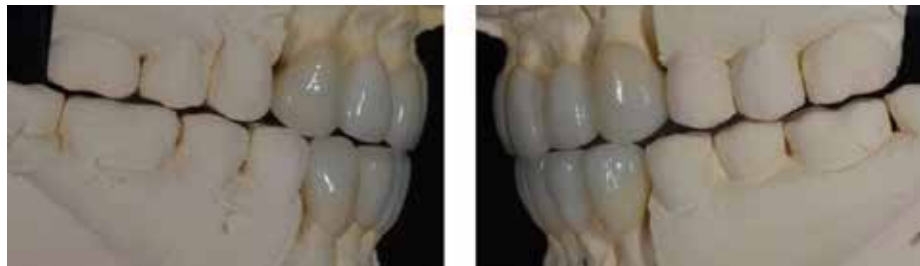

Lithium disilicate & Porcelain veneering



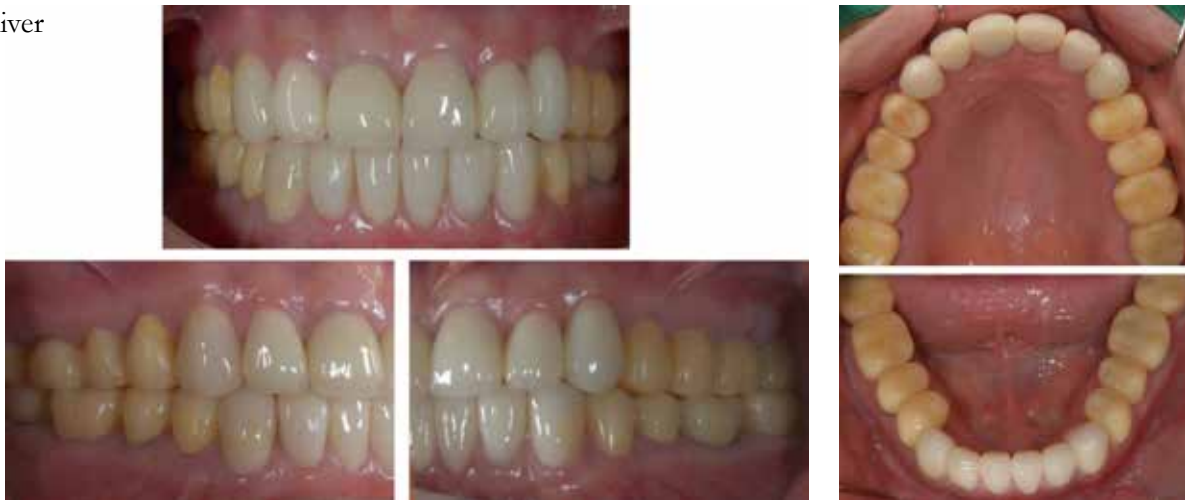MI

protrude

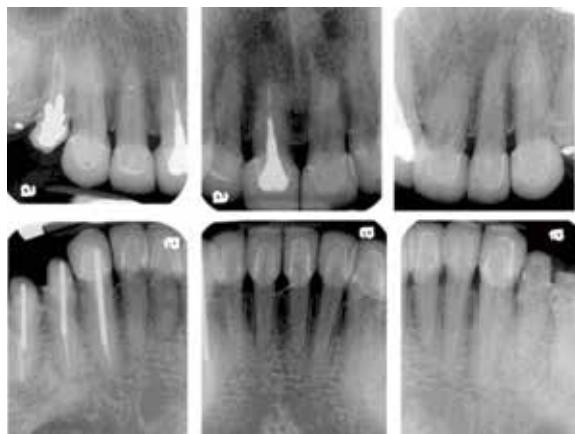


Working

Deliver

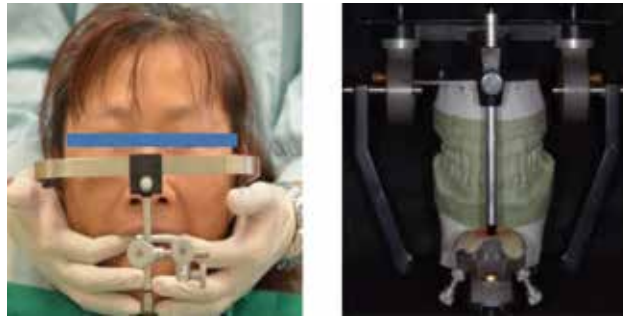

Periapical film

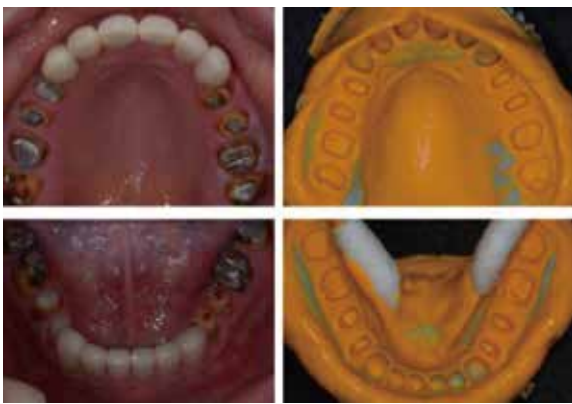

Definite restoration - posterior teeth

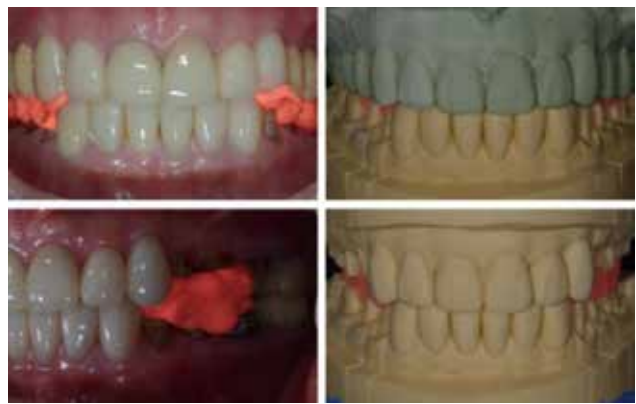Facebow transfer



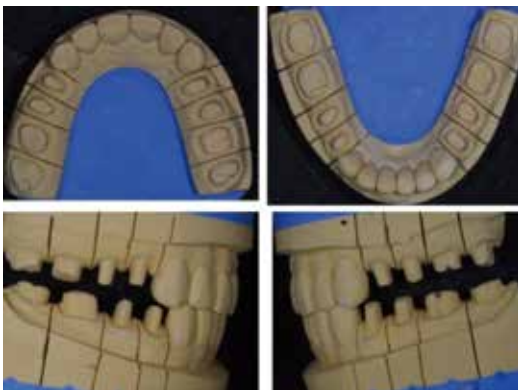
Impression




Bite and cross mounting



Master cast

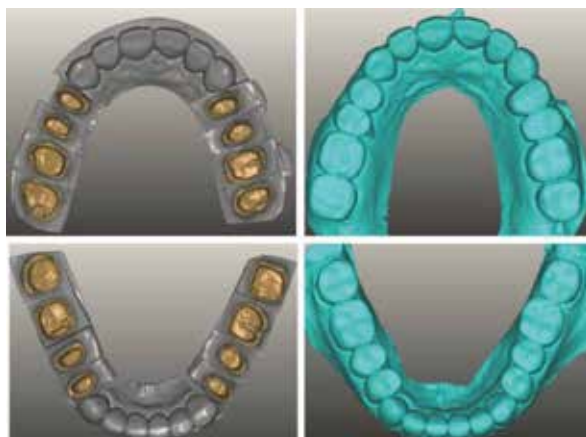


CAD-CAM scan



Working cast

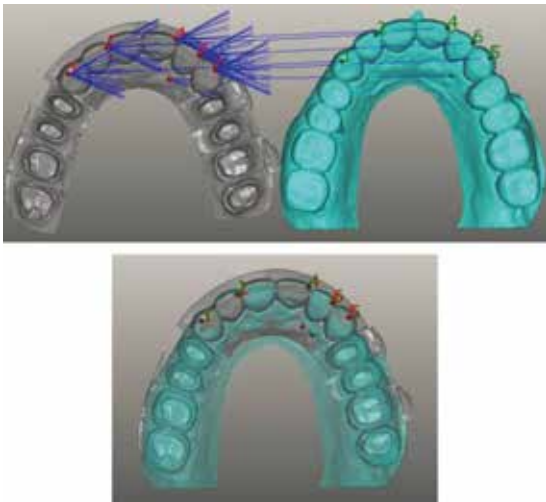
Provisional



Mounting



Overlapping



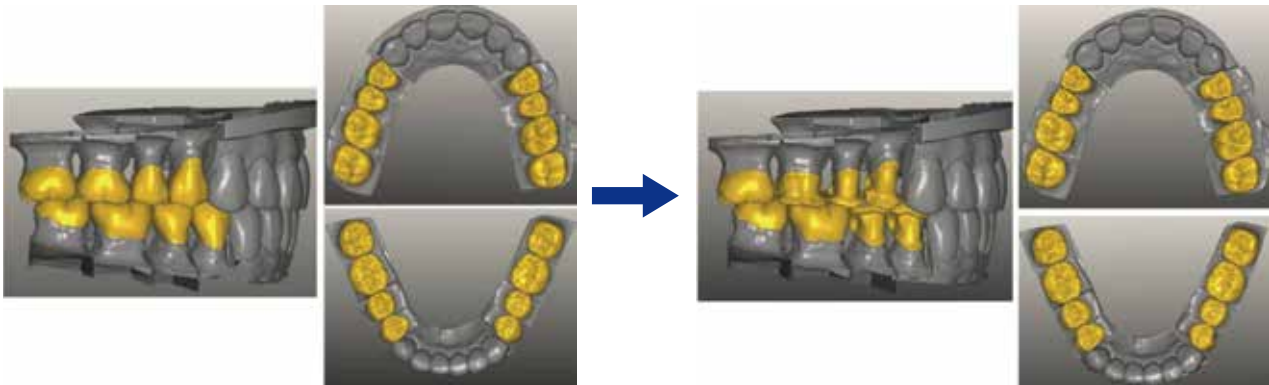
Check provisional thickness




Provisional simulation



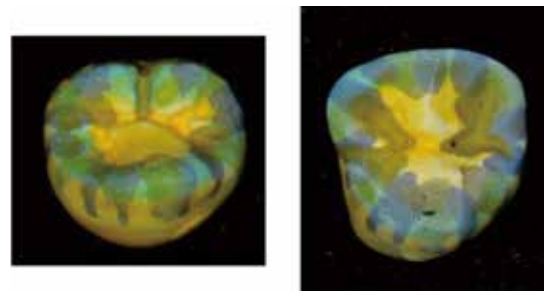
Full contour



Milling



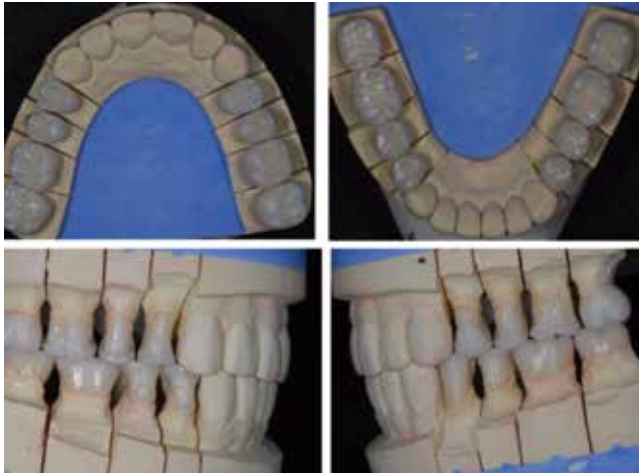Coloring



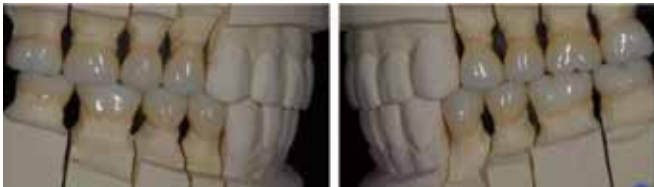
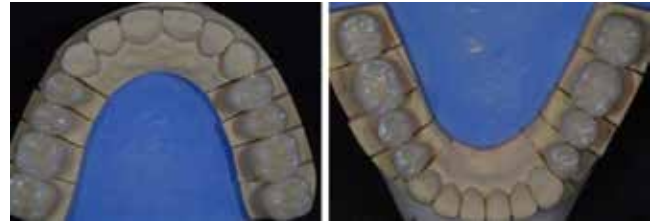
病例讨论专栏

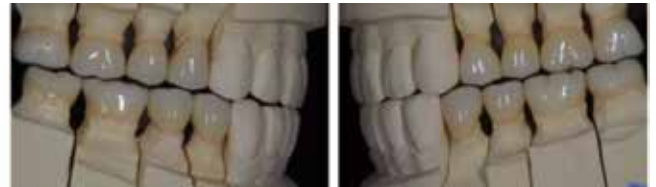Zirconia coping



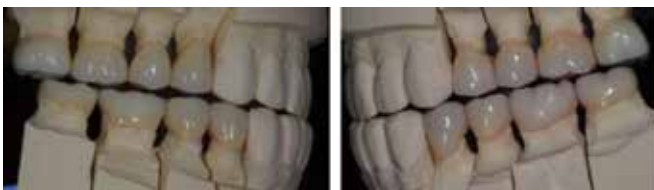Veneering



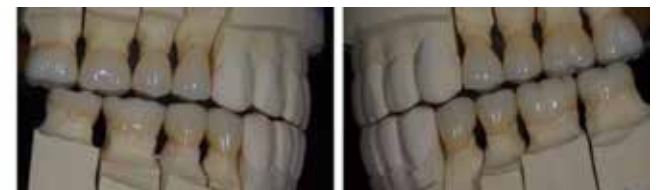MI



Working

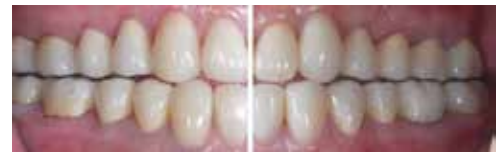
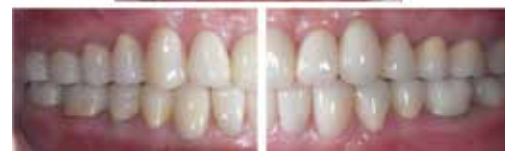
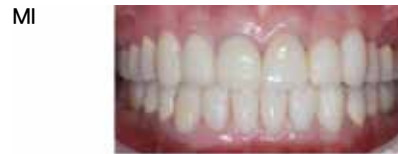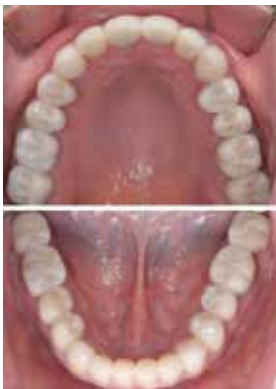Protrude

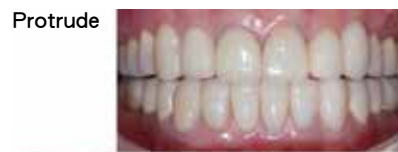

Balancing

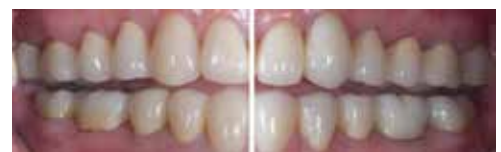Deliver



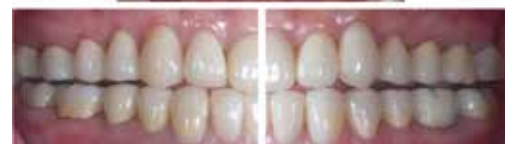Working

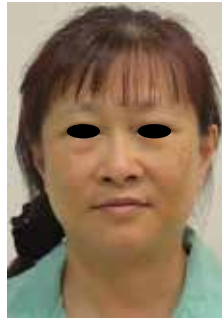
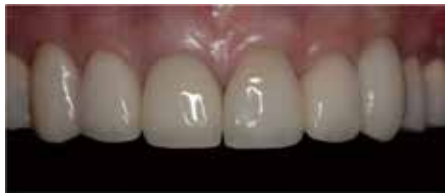
Protrude

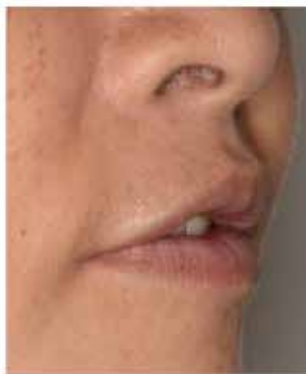

Balancing

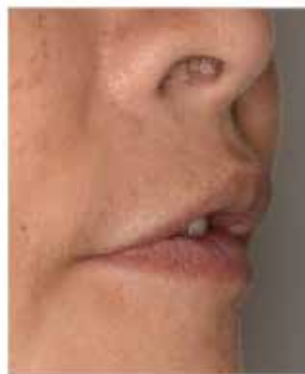



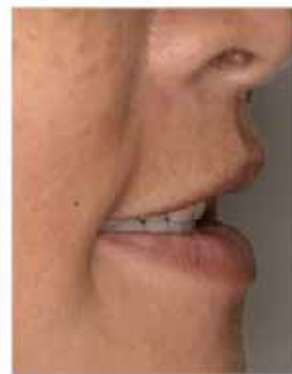Phonetic test



"F"



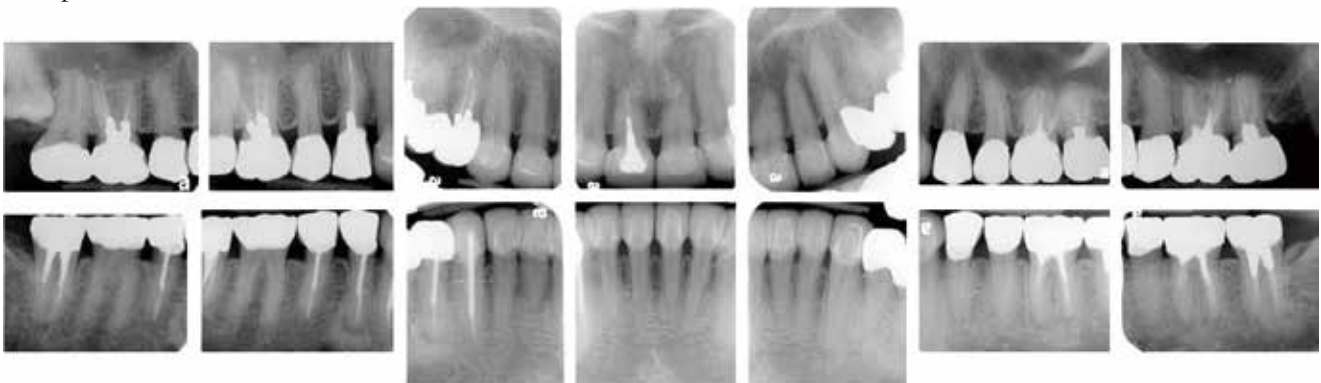
"V"



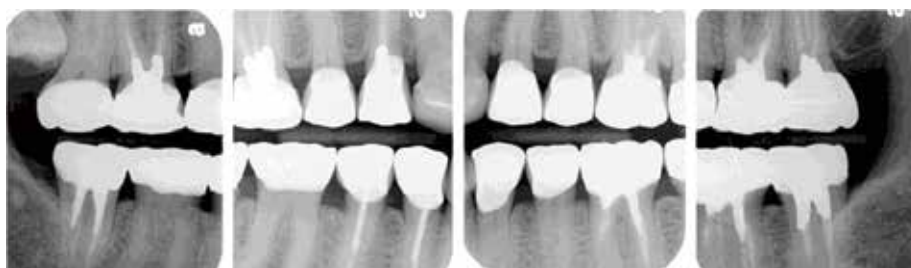
"S"

X-ray examination

Periapical film



Bite-wing film



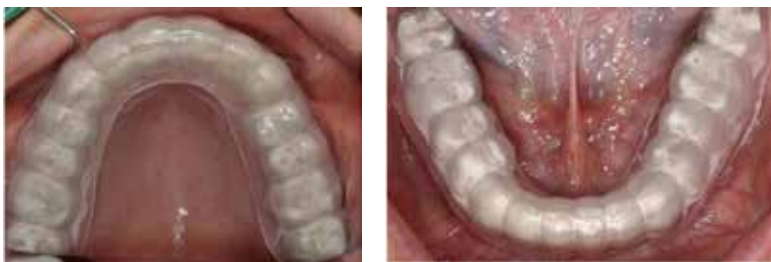Plaque index

9%, O'Leary

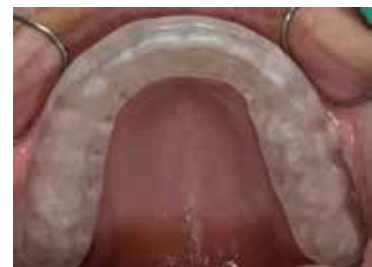	17	16	15	14	13	12	11	21	22	23	24	25	26	27
F	000	001	000	000	000	001	100	000	000	000	100	000	000	001
P	100	100	000	000	000	100	000	000	000	000	000	000	000	100

	47	46	45	44	43	42	41	31	32	33	34	35	36	37
L	000	100	000	000	000	000	000	000	001	000	100	000	000	000
F	100	000	000	000	000	000	000	000	000	000	100	000	000	001

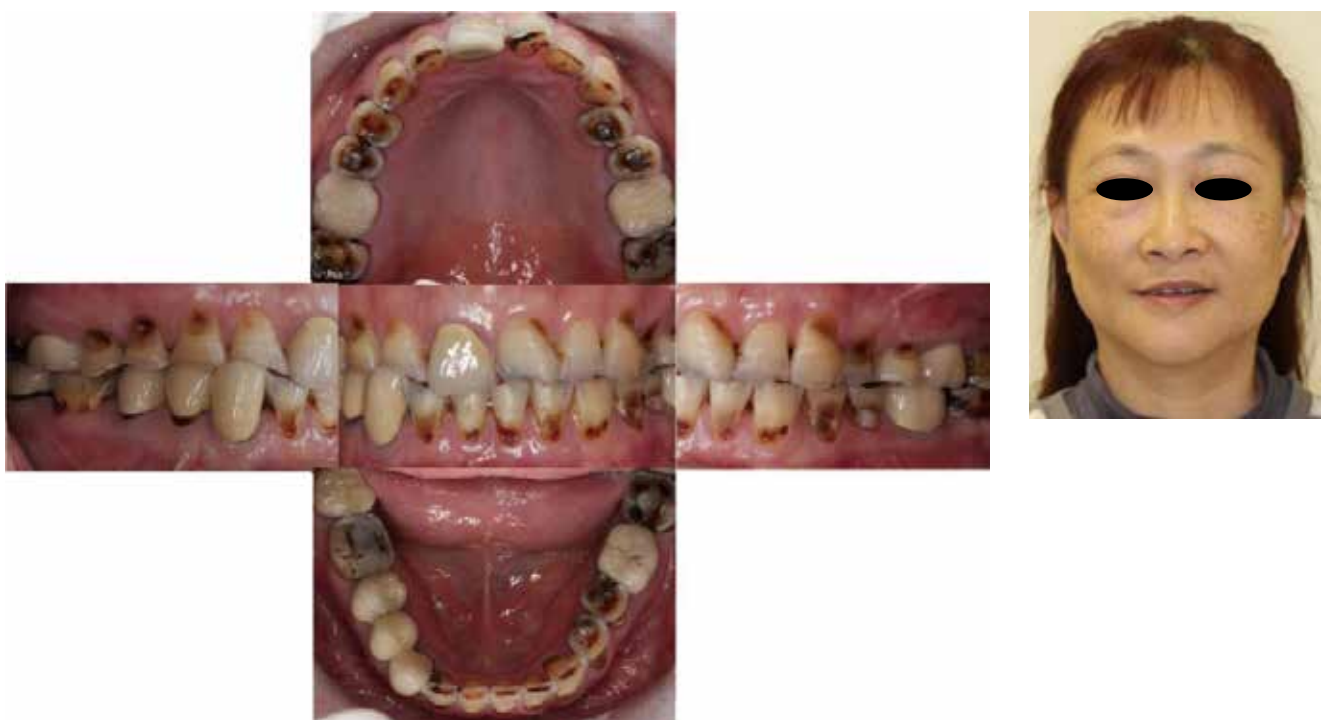
Fluoride tray



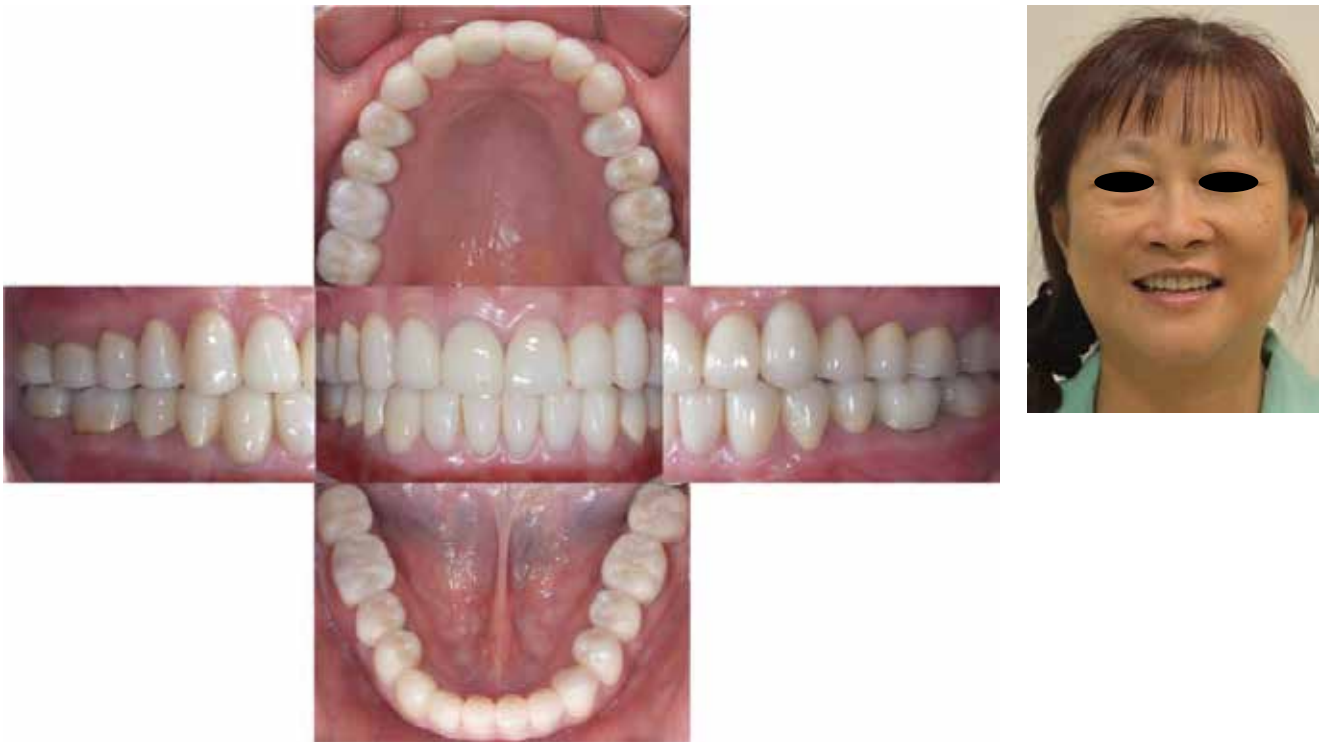Night guard



术前



術後



Q1：印模前的VD是當初欲提高的VD嗎？如何確認？

A1：印模前check provisional厚度，只要是達到我們原本的目的：足夠的贖復空間即可。最後實際提高的VD無法非常精確的確認。

Q2：治療期間做了第二組的前牙provisional，是否可以直接在口內修改第一組即可，不需再次wax-up？

A2：病患家人提出的意見是認為“上顎前牙包住下顎前牙太多，而且太長”，意思是希望上前牙長度縮短，並讓上下牙齒比較接近edge-to-edge的排列，修改項目比較多。當初是想減省臨床時間，並保留原本第一組的provisional讓病患有可以反悔的機會，所以又做了一組新的前牙。