

上顎半口義齒及 下顎甘迺迪分類第一類 可撤式局部活動義齒

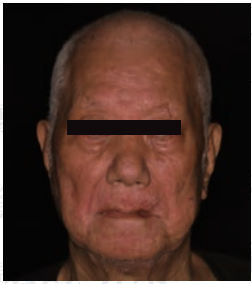
報告者：陳建豪 醫師

指導醫師：彭嫻晴 醫師

Key words:

CAD/CAM, dementia

General Data



- Name: 胡 O 官
- Gender: Male
- Age: 86 y/o
- Date of first OPD: 2023/04/18
- Date of first visit: 2023/09/18
- Occupation: none
- Psychological state: N/A, Dementia

Present Illness

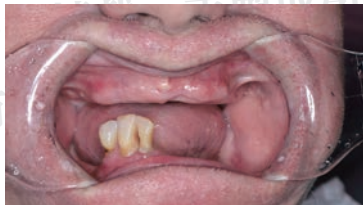- This 86 y/o male suffered from inability to chew, and came to our OPD for denture reconstruction of his dentition.

Past History

- Past Medical History
 - Dementia
 - Wheelchair-seating for leg amputation
 - Denied other major systemic disease and drug allergy

Chief Complaint

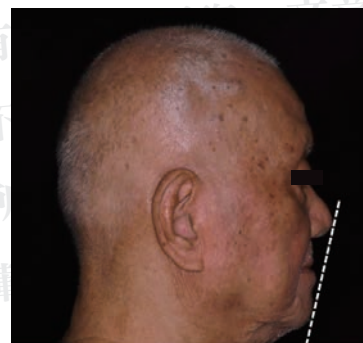
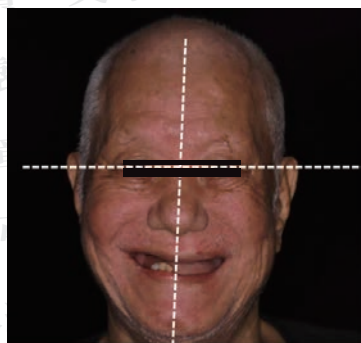
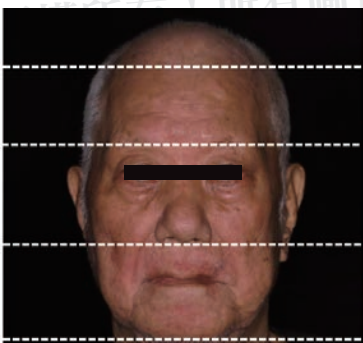Asking for full mouth rehabilitation with government subsidy.



- Past Dental History
 - Denture fabricated at LDC over 15 years ago, discarded
 - 2023/05/22~07/04 multiple teeth ext at OS
- Personal habit
 - ABC: nil

Clinical Examination

Extra-oral Findings



- Ovoid-shaped face
- Facial proportion = 1 : 1.28 : 1.22
- Lip incompetence: (-)
- Mentalis m. strain: (-)
- Facial symmetry: axis deviated to Rt, left facial muscle hypoactivity
- Midline: Upper: N/A, lower: N/A
- Smile line: N/A
- Profile: Straight
- Upper/lower lip to E line: U, L retruded
- Nasolabial angle: >90°

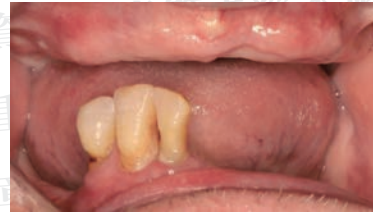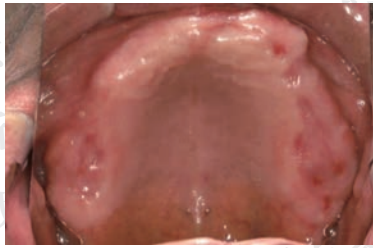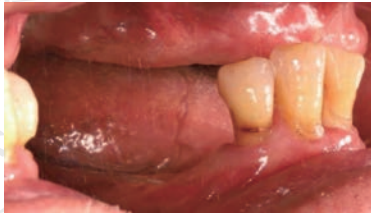TMJ-related Examination

- No TMD history
- Maximum mouth opening: 46 mm (ridge-43)
 - Mouth opening deviation: (-)
- TMJ palpation pain: (-)
- Muscle tenderness: (-)
- Clicking sound: (-)

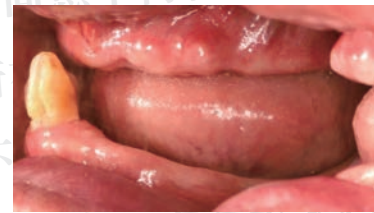Intra-oral Findings

- Canine relationship:
 - N/A

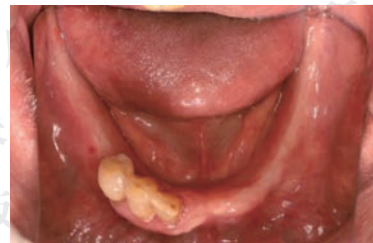- Molar relationship:
 - N/A



- Upper dentition
 - Arch form: square
 - Full arch edentulism
 - Exotosis w/ tissue undercut
 - Ridge (Atwood order III)

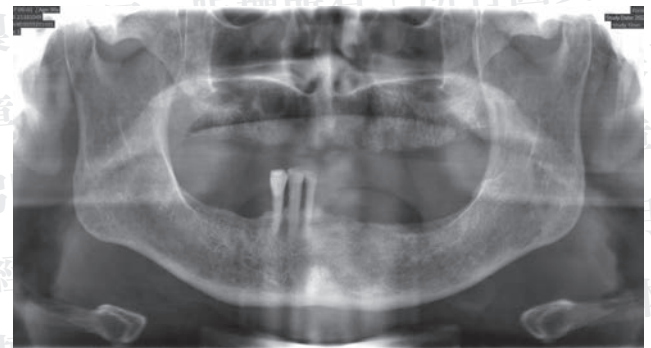
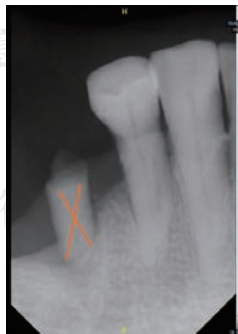
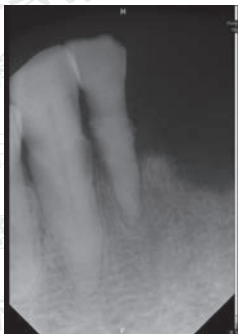
- Unsmooth occlusal plane



- Lower dentition
 - Arch form: ovoid
 - Missing: 31-38, 41, 45-48
 - Ridge (Atwood order III)
 - 44 (DL) Caries

Radiographic findings



- 45 retained root s/p extraction
- Compromised periodontium, C/R > 1

- Upper complete edentulism,
lower remained dentition 42-44

FM periodontal status

PD	42	43	44
B (M->D)	2 2 3	3 3 3	3 3 4
L (D->M)	3 3 2	4 3 3	4 3 4
Mob	I	0	0

Assessment

Diagnosis

- 18-28, 31-38, 41, 45-48 missing
- 44 (DL) root caries
- Generalized periodontitis: stage IV, grade B

	Periodontitis	Stage I	Stage II	Stage III	Stage IV
Severity	Interdental CAL (at site of greatest loss)	1-2 mm	3-4 mm	≥5 mm	≥5 mm
	RBL	Coronal third (<15%)	Coronal third (15% - 33%)	Extending to middle third of root and beyond	Extending to middle third of root and beyond
	Tooth loss (due to periodontitis)	No tooth loss		≤4 teeth	≥5 teeth
Complexity	Local	<ul style="list-style-type: none"> • Max. probing depth ≤4 mm • Mostly horizontal bone loss 	<ul style="list-style-type: none"> • Max. probing depth ≤5 mm • Mostly horizontal bone loss 	In addition to Stage I complexity: <ul style="list-style-type: none"> • Probing depths ≥6 mm • Vertical bone loss ≥3 mm • Furcation involvement Class II or III • Moderate ridge defects 	In addition to Stage III complexity: <ul style="list-style-type: none"> • Need for complex rehabilitation due to: <ul style="list-style-type: none"> - Masticatory dysfunction - Secondary occlusal trauma (tooth mobility degree ≥2) - Severe ridge defects - Bite collapse, drifting, flaring - <20 remaining teeth (10 opposing pairs)
Extent and distribution	Add to stage as descriptor	For each stage, describe extent as: <ul style="list-style-type: none"> • Localized (<30% of teeth involved); • Generalized: or • Molar/incisor pattern 			

	Progression		Grade A: Slow rate	Grade B: Moderate rate	Grade C: Rapid rate
Primary criteria Whenever available, direct evidence should be used.	Direct evidence of progression	Radiographic bone loss or CAL	No loss over 5 years	<2 mm over 5 years	≥2 mm over 5 years
	Indirect evidence of progression	% bone loss / age	<0.25	0.25 to 1.0	>1.0
Case phenotype		Heavy biofilm deposits with low levels of destruction	Destruction commensurate with biofilm deposits	Destruction exceeds expectations given biofilm deposits; specific clinical patterns suggestive of periods of rapid progression and/or early onset disease	
Grade modifiers	Risk factors	Smoking	Non-smoker	<10 cigarettes/day	≥10 cigarettes/day
		Diabetes	Normoglycemic/no diagnosis of diabetes	HbA1c<7.0% in patients with diabetes	HbA1c ≥7.0% in patients with diabetes

Problem list

- Dementia
- Loss of masticatory function
- Compromised esthetics
- Unilateral, limited, straight-aligning abutments

Expectation

- Declined surgery in consideration to physical status and economic reason

Plan

Treatment goal

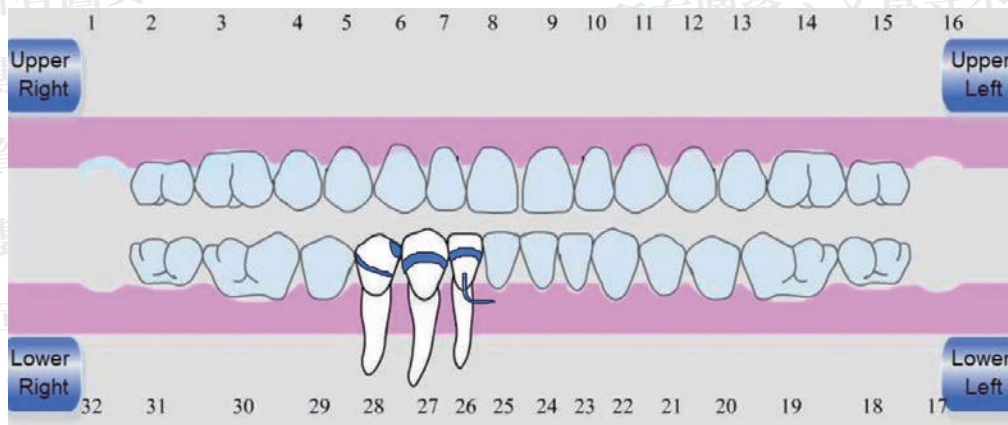
- Restore chewing function and esthetics
- Maintainable and repairable

Treatment plan

- FM supportive periodontal therapy and OHI
- 44 OD
- Upper complete denture and lower removable partial denture
 - Semidigital workflow

Prosthetic treatment plan

- Upper CD and lower RPD

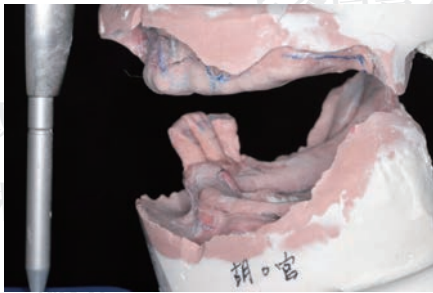
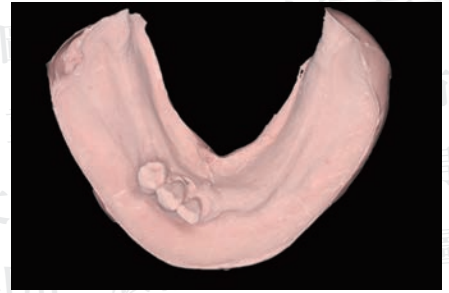
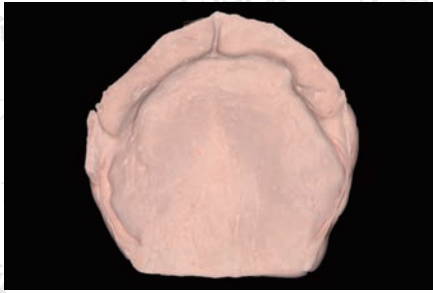


Treatment sequence

- 2023/09/18: Initial record
- 2023/10/23: 44 OD, upper final impression with individual tray
- 2023/10/25: Guiding plane preparation with guide, bite record with recording base
- 2023/11/09: Occlusal plane leveling and mouth preparation with guide, 1st digital trial denture
- 2023/11/15: Border molding, final impression with L individual tray
- 2023/12/01: Lower f/w try-in, bite record with gothic arch, shade selection
- 2024/12/22: Upper and lower 2nd digital trial denture try-in
- 2024/01/06: Upper CD, lower RPD delivery
- 2024/01/08~2024/07/09: 2D, 1W, 1M, 3M, 6M Follow-up

Treatment course

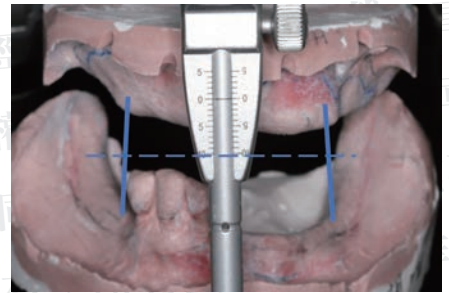
Study cast for initial evaluation



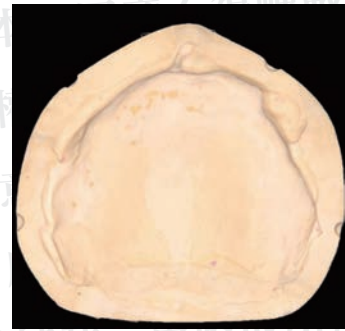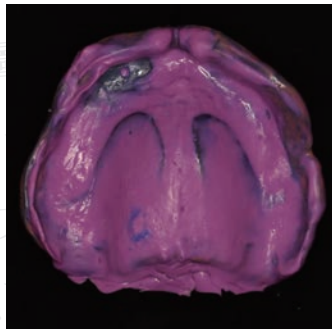
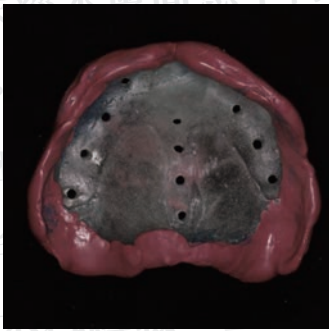
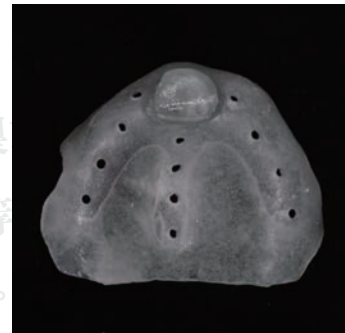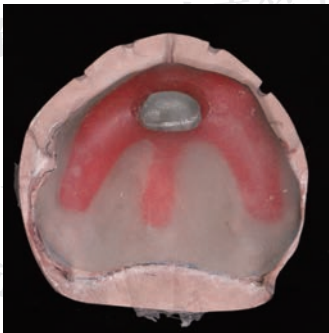Ridge relationship

Anterior: Class I

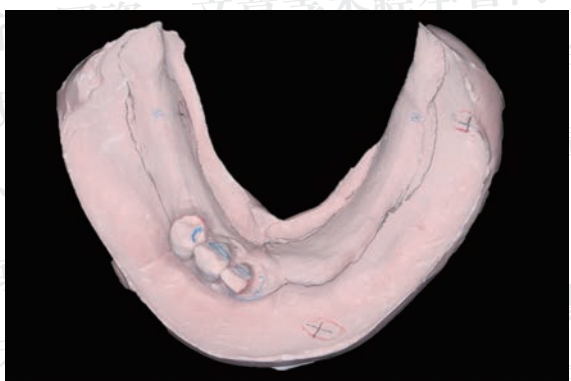
Posterior: Class I



Upper individual tray & final impression

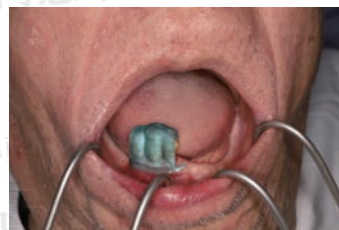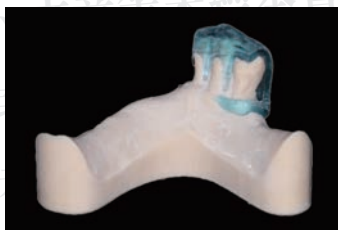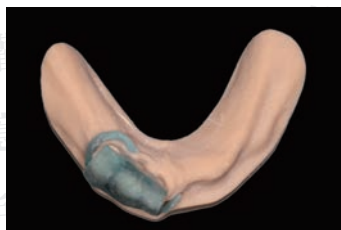


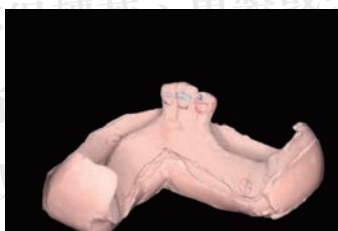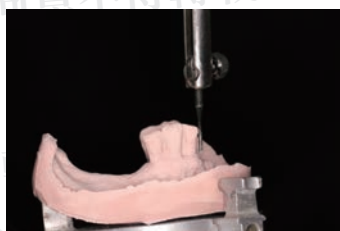


Lower denture design and survey

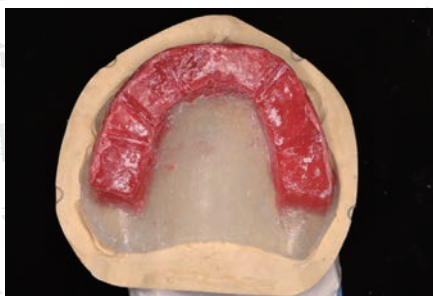
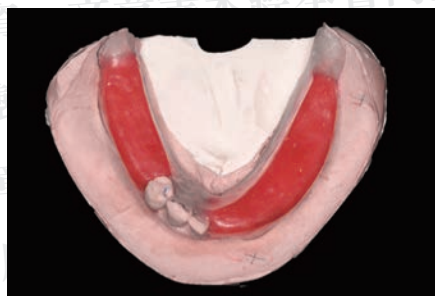
- Guiding plane: 42M, 44DL
- Rest: 42,43 cingulum, 44 M
- Direct retainer: 42 I bar, 44 w wire circumferential clasp
- Major connector: Lingual plate (tooth replacement)
- Artificial tooth: 31-37, 41, 45-47

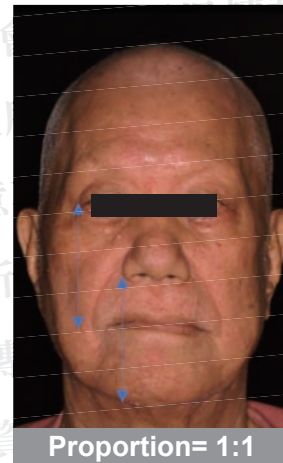
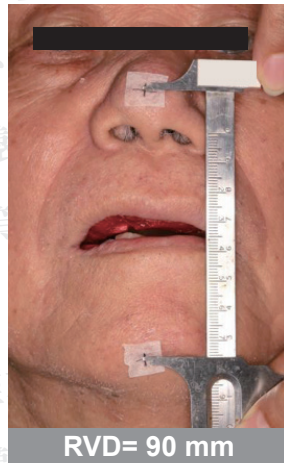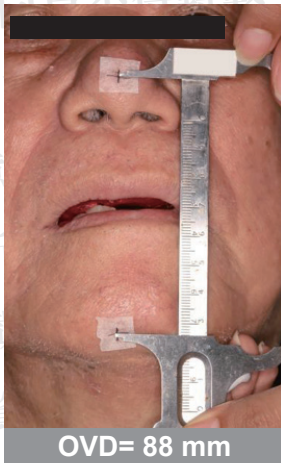
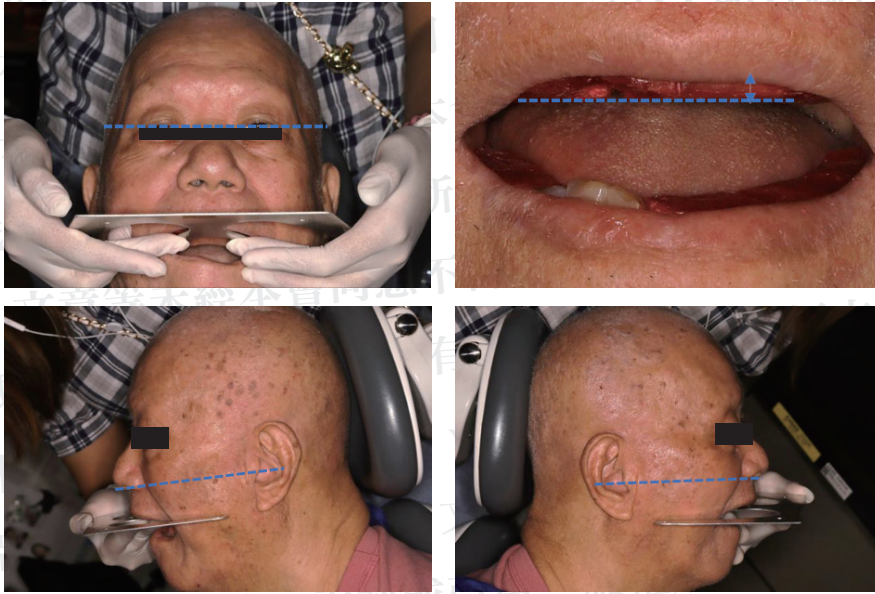
Guiding plane design, digital preparation guide



Recording base and wax rim



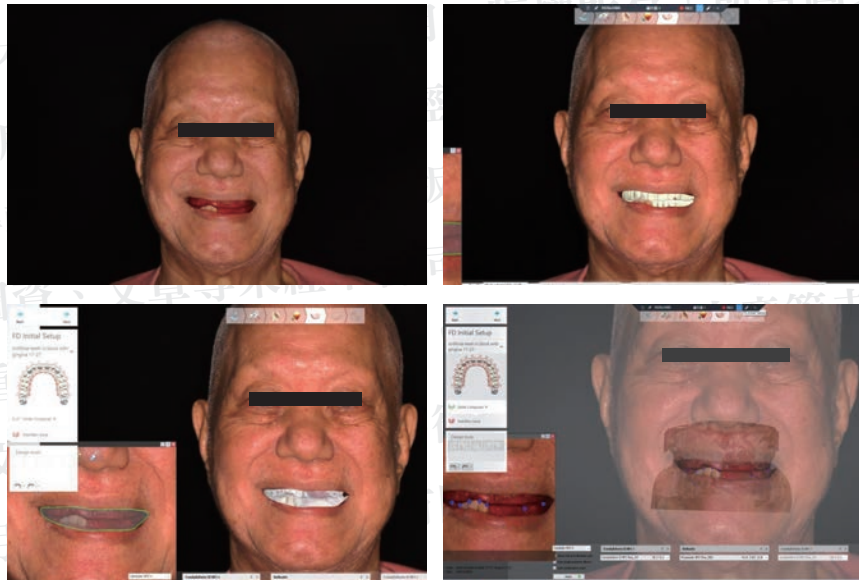Occlusal plane, and vertical dimension determination



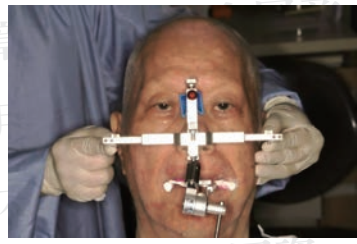
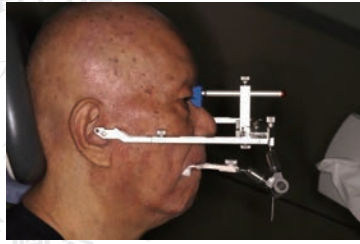
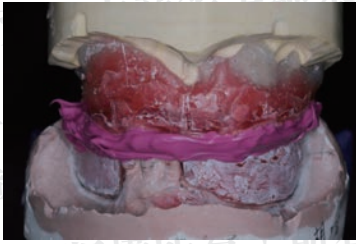$$\text{VDO} = \text{VDR}(90) - \text{freeway space (2-4)} = 88$$

Digital denture design

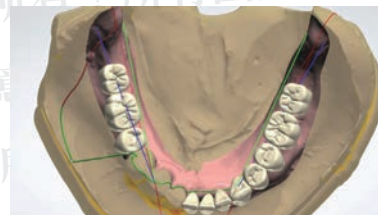
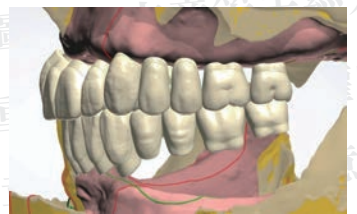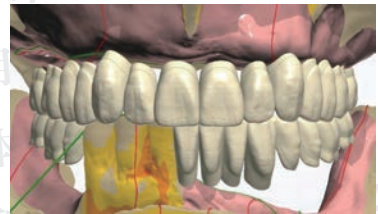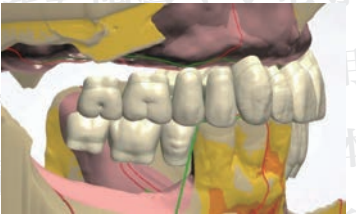
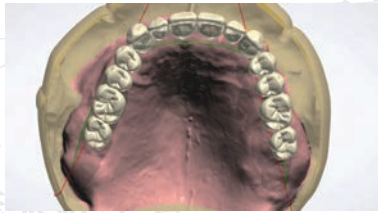
- Ivoclar DCL tooth form



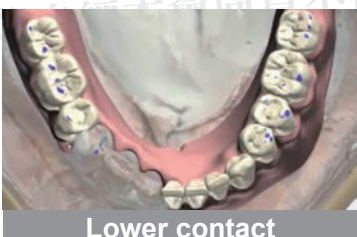
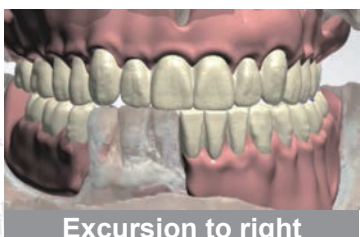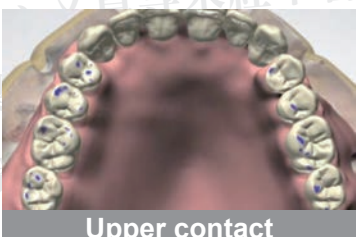
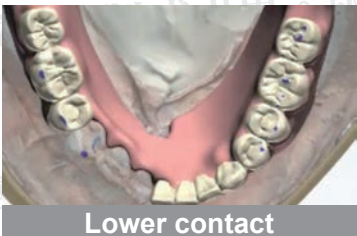
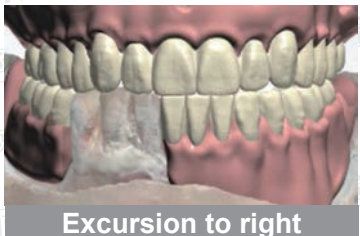
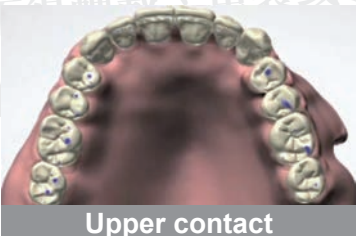
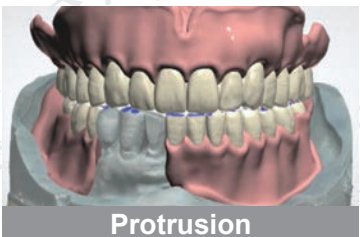
Bite registration and facebow transfer



Digital design

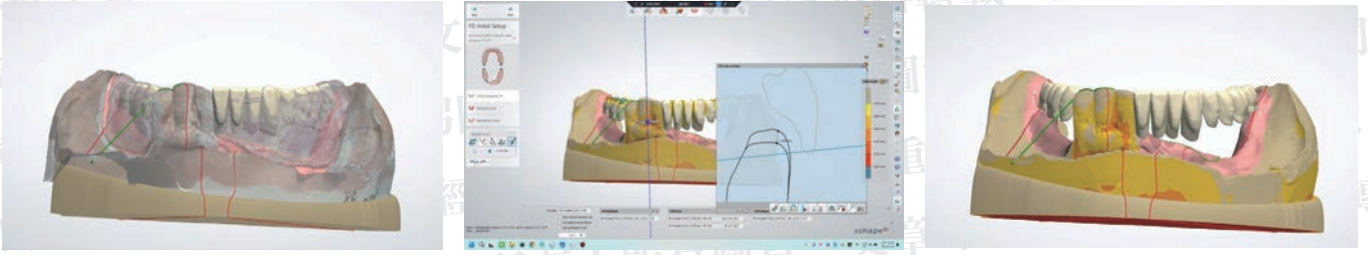


Group function

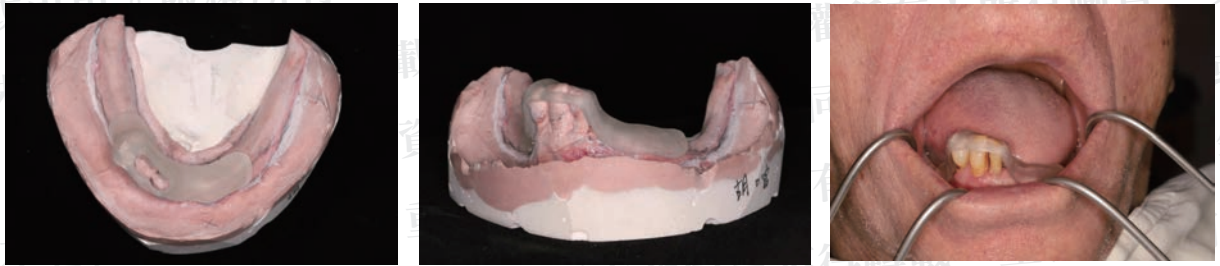


Digital occlusal adjustment design

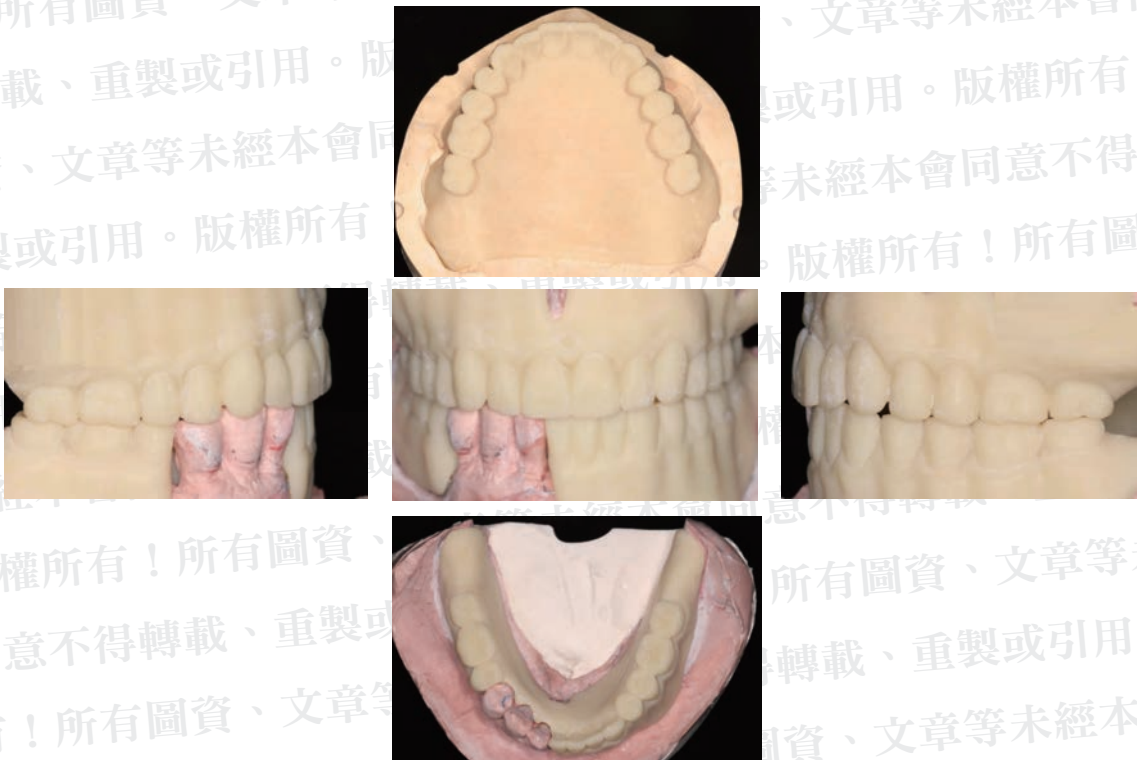
- Reduction 1.35 mm at 43, 0.3 mm at 42



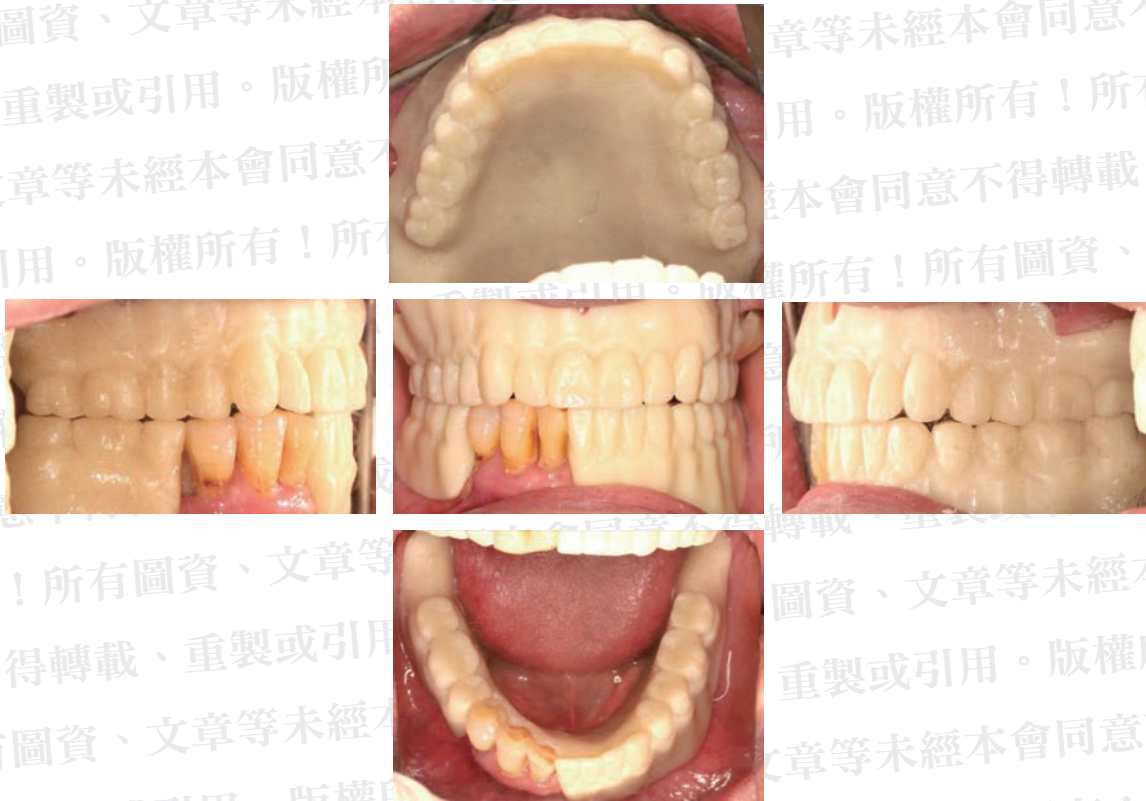Digital occlusal adjustment guide



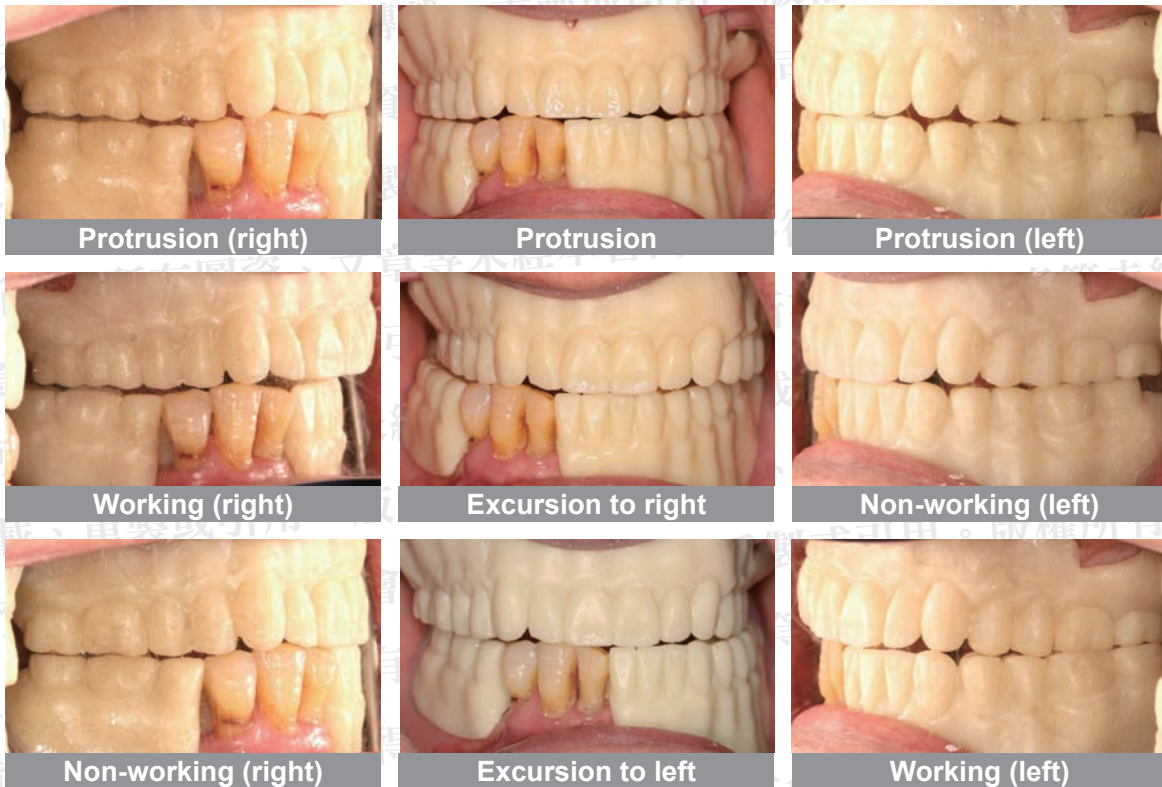1st Digital trial denture



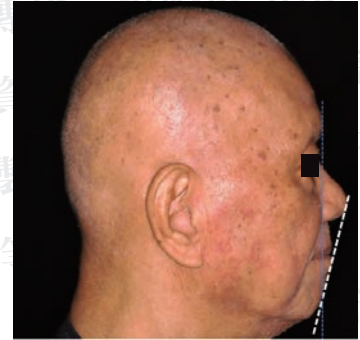
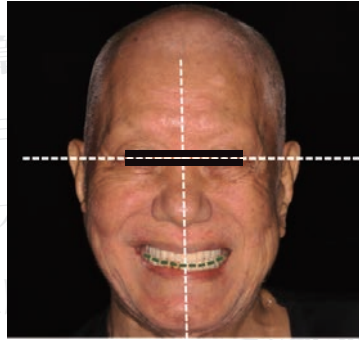
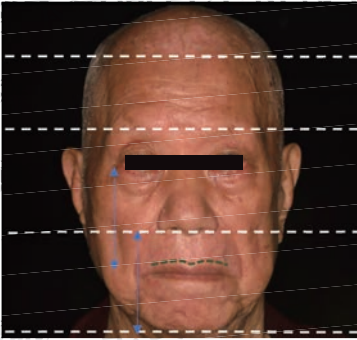
1st Digital Trial denture Intra-oral



Eccentric movement Fully balanced occlusion

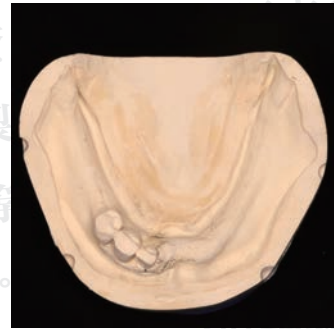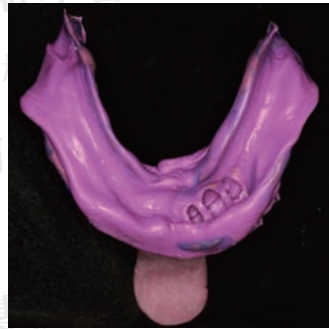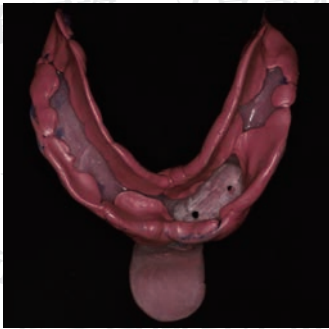


Extra-oral: VD and esthetic assessment

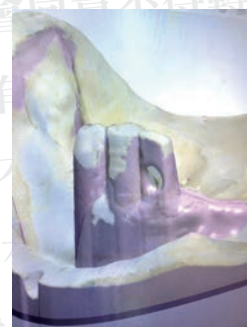
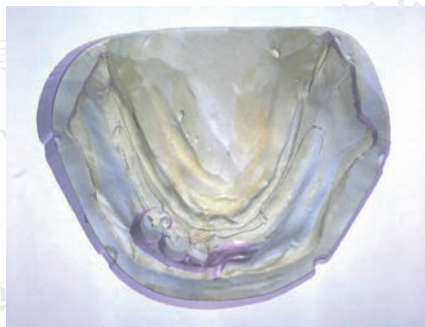

- Ovoid-shaped face
- Facial proportion = 1 : 1.28 : 1.31
- Canthus-commissure = alar-chin
- Lip support
 - Smooth cupid's bow support
 - Light vermillion border
- Facial dental midline: Upper: on, lower: on, chin: to Lt
- Average smile line, no gummy smile
- Occlusal plane: // lower lip except Rt depressor labii inferioris
- Profile: Straight
- Upper/lower lip to E line: U mild retruded, L on
- Lip support
 - Nasolabial angle: >90°, decreased
 - Philtrum: shallow concave

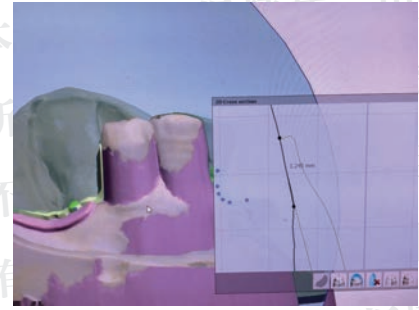
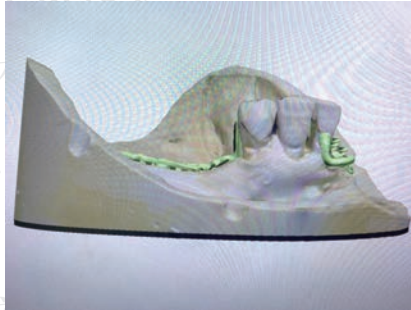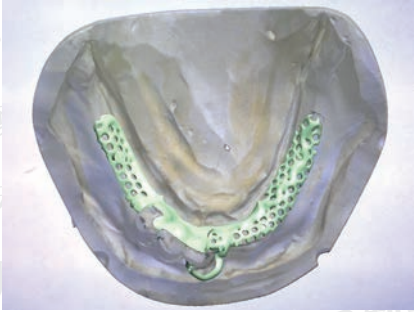Lower border molding, final impression



Survey, block out undercut on virtual analog cast



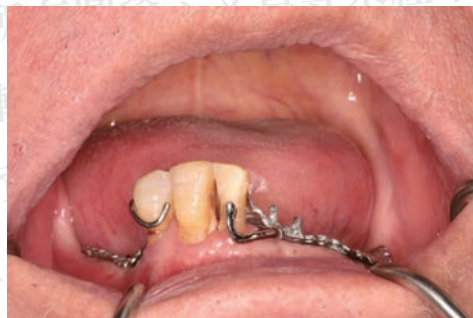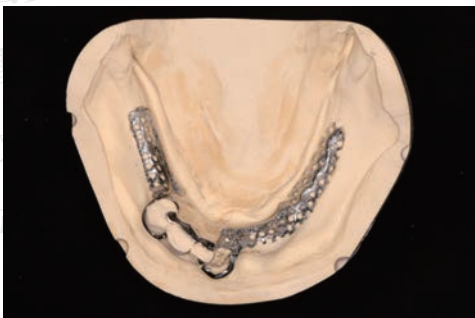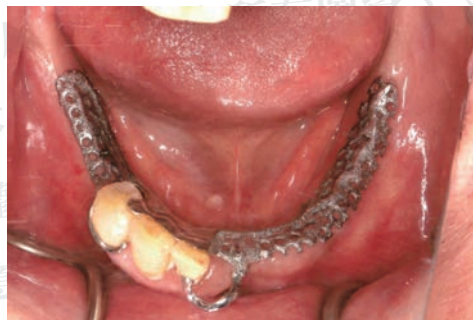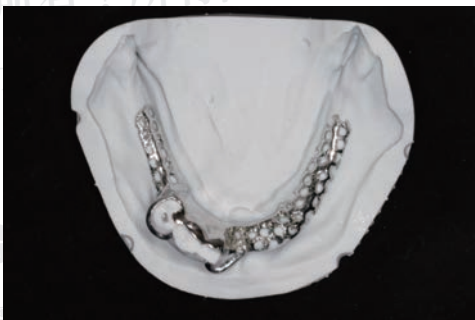Digital framework design



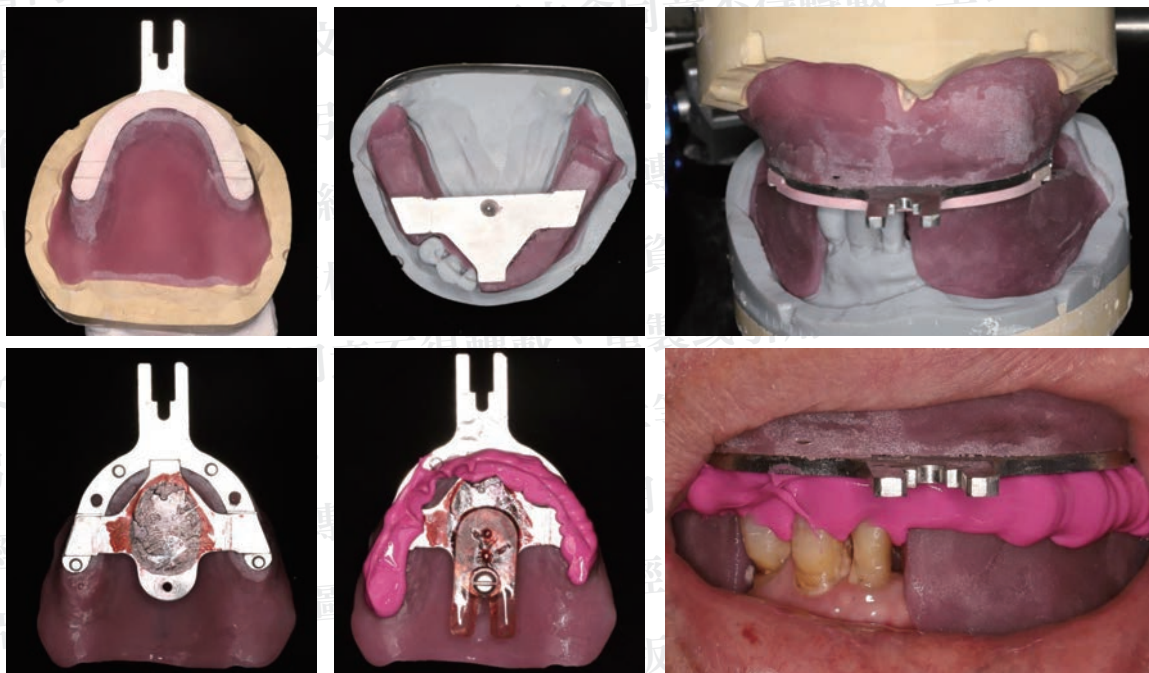
- Lingual plate, 42 I-bar, 44 ww clasp, 42C 43C 44M rest
- Verifying 1 mm contact of short proximal plate

Digital framework design

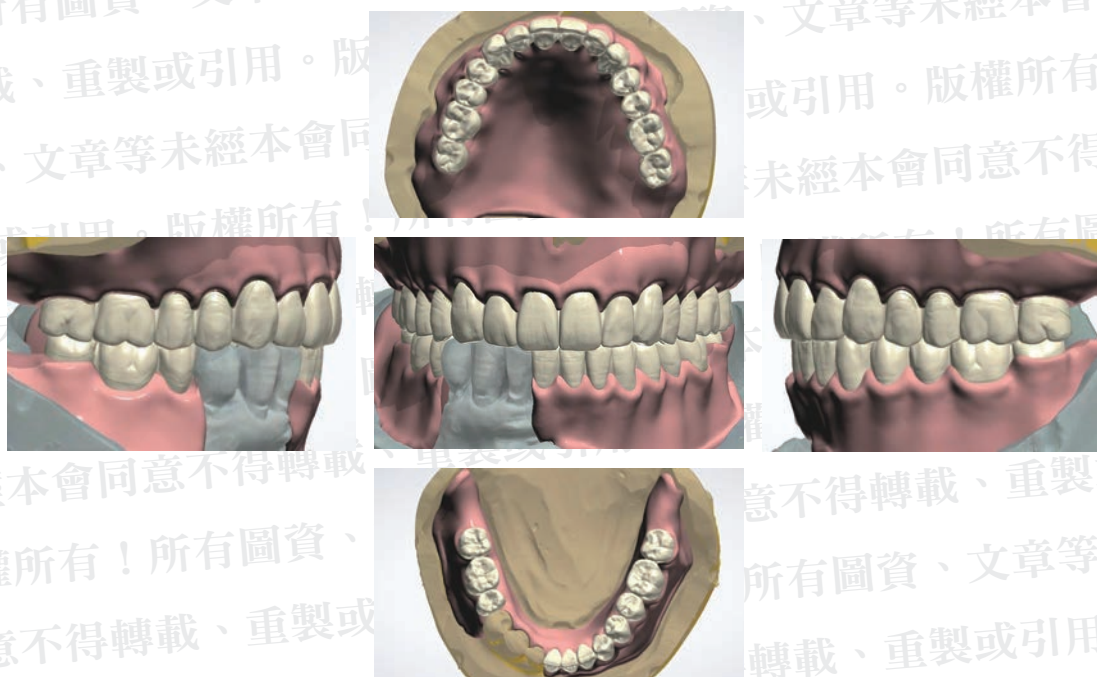
WW clasp soldered on
3D-printed (Selective laser melting) Co-Cr alloys F/W



Bite registration with gothic arch

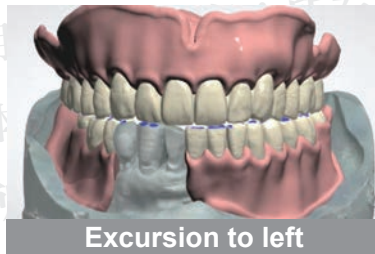
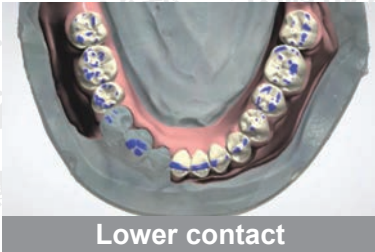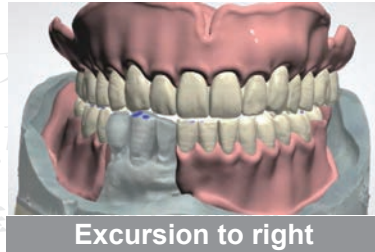
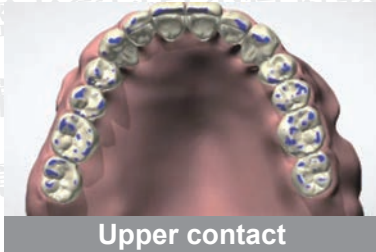
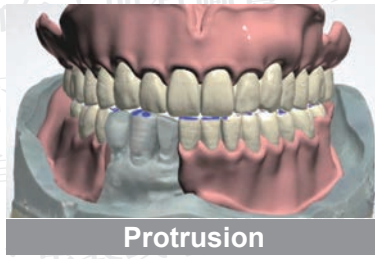


2nd Digital Denture design

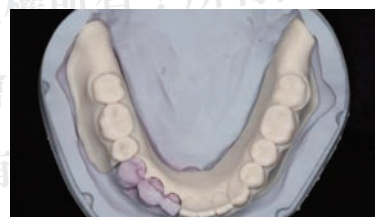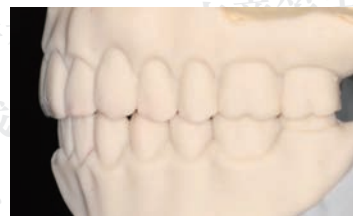

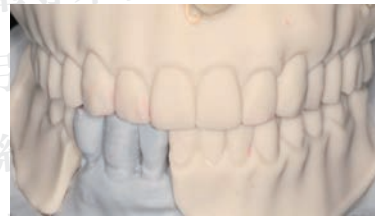
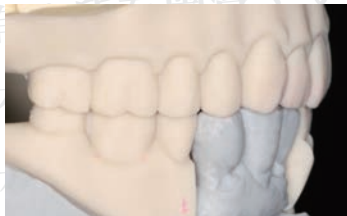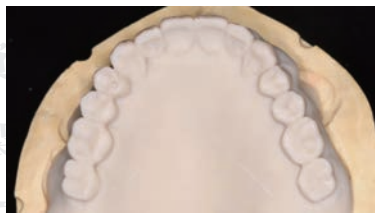Eccentric movement

Fully balanced occlusion

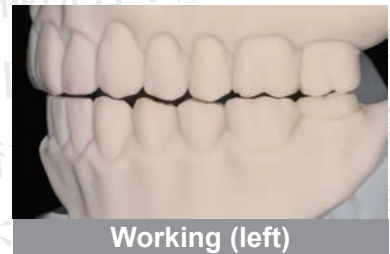
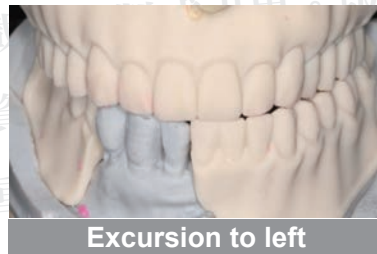
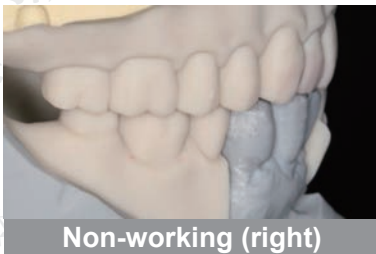
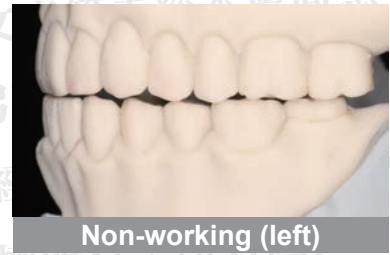
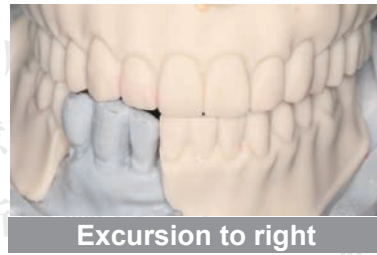
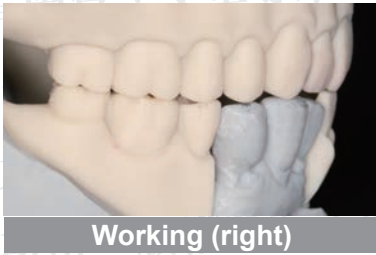
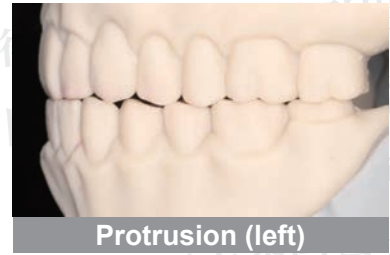
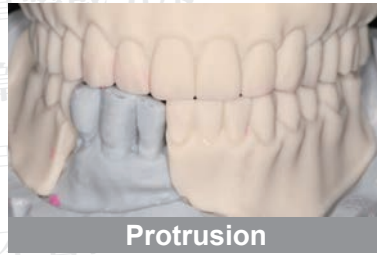
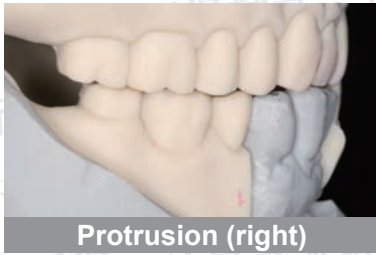


2nd Digital Trial Denture

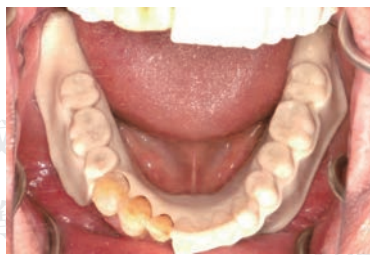
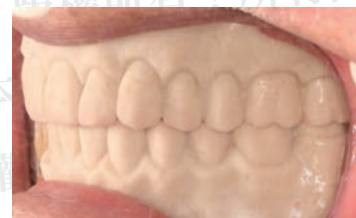
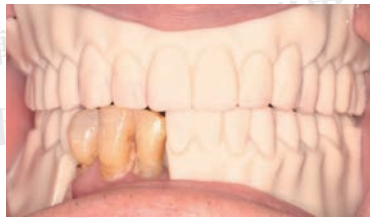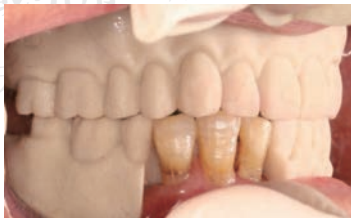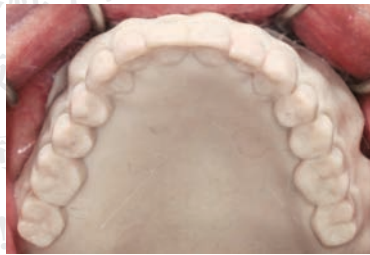Eccentric movement

Fully balanced occlusion

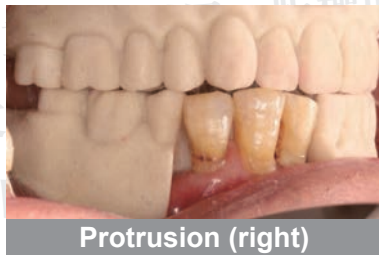

Try-in: Occlusion

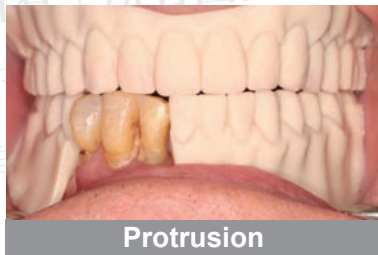


Eccentric movement

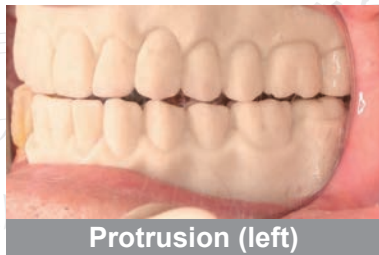
Fully balanced occlusion



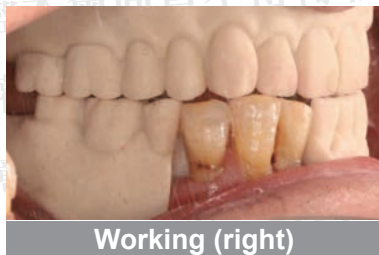Protrusion (right)



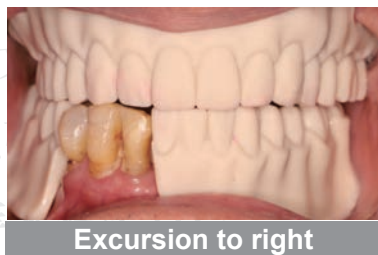Protrusion



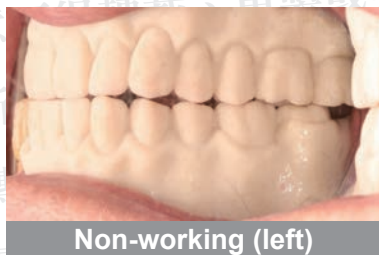Protrusion (left)



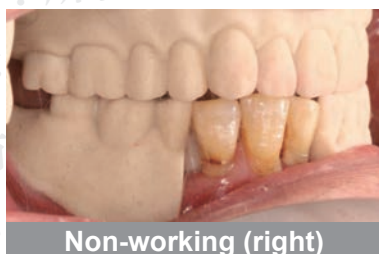
Working (right)



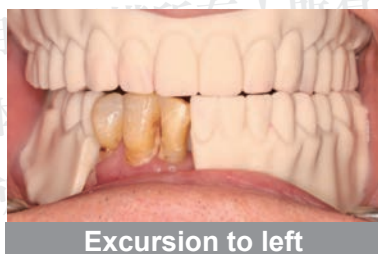Excursion to right



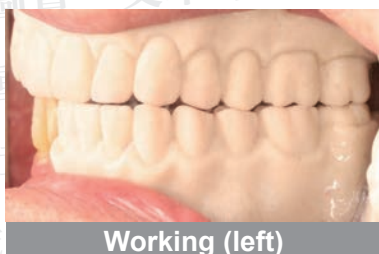Non-working (left)



Non-working (right)



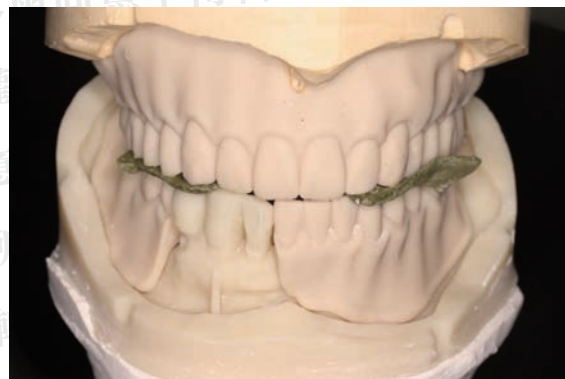
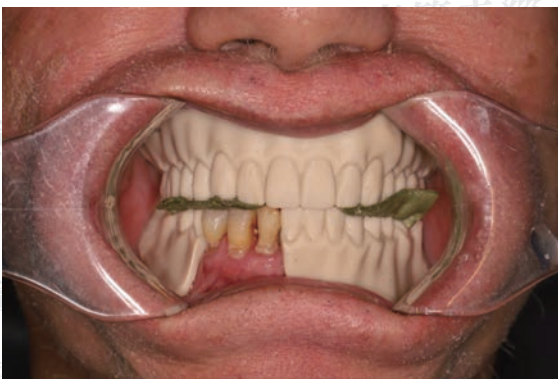Excursion to left



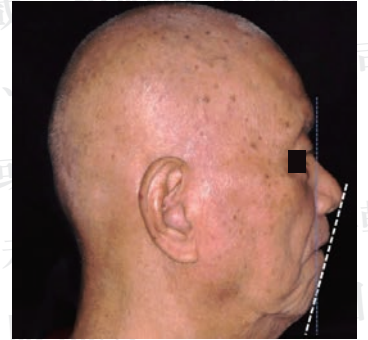
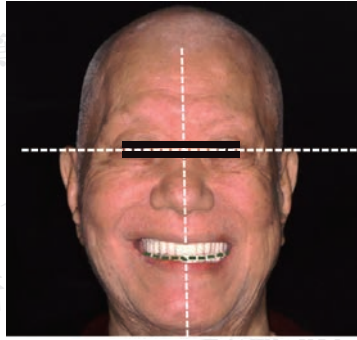
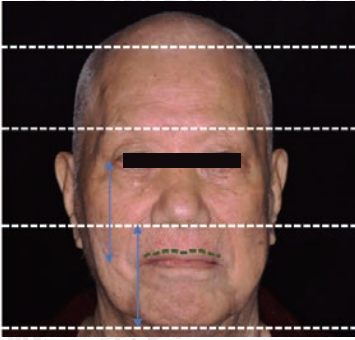
Working (left)

Try-in: occlusion verification

- Check intra-oral CO (CR position) in accordance with articulator's bite

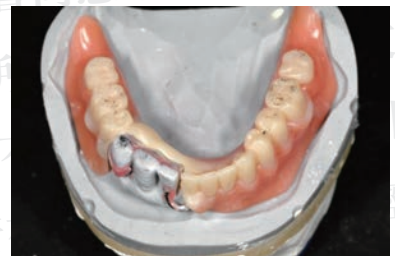
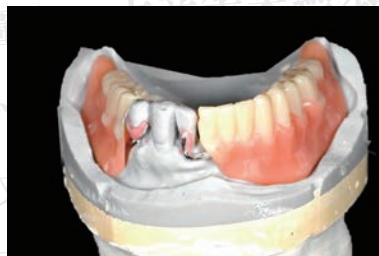
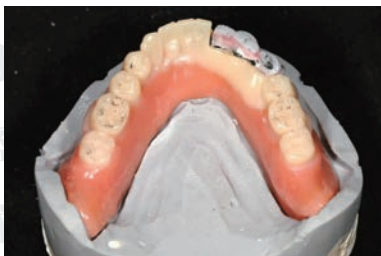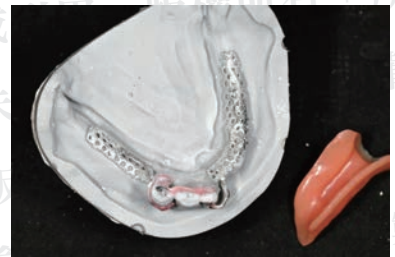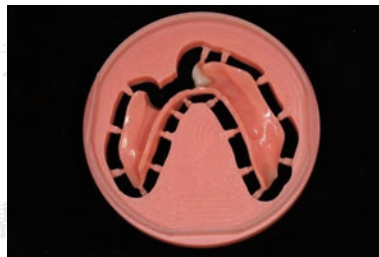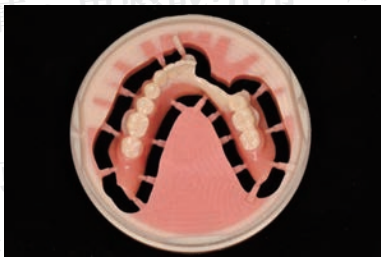Try-in: VD and esthetic assessment

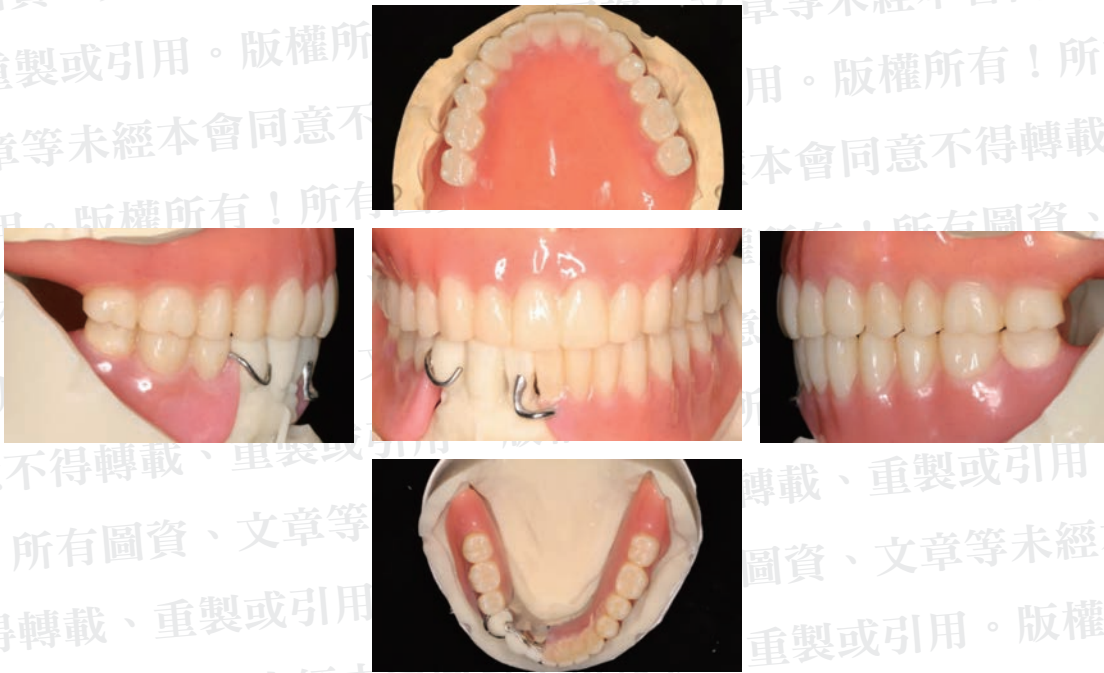

- Ovoid-shaped face
- Facial proportion = 1 : 1.22 : 1.25
- Canthus-commissure = alar-chin
- Lip support
 - smooth cupid's bow support
 - light vermillion border
- Facial dental midline: Upper: on, lower: on, chin: to Lt
- Average smile line, no gummy smile
- Occlusal plane: // lower lip except Rt depressor labii inferioris
- Profile: Straight
- Upper/lower lip to E line: U mild retruded, L on
- Lip support

Assembly of base onto framework



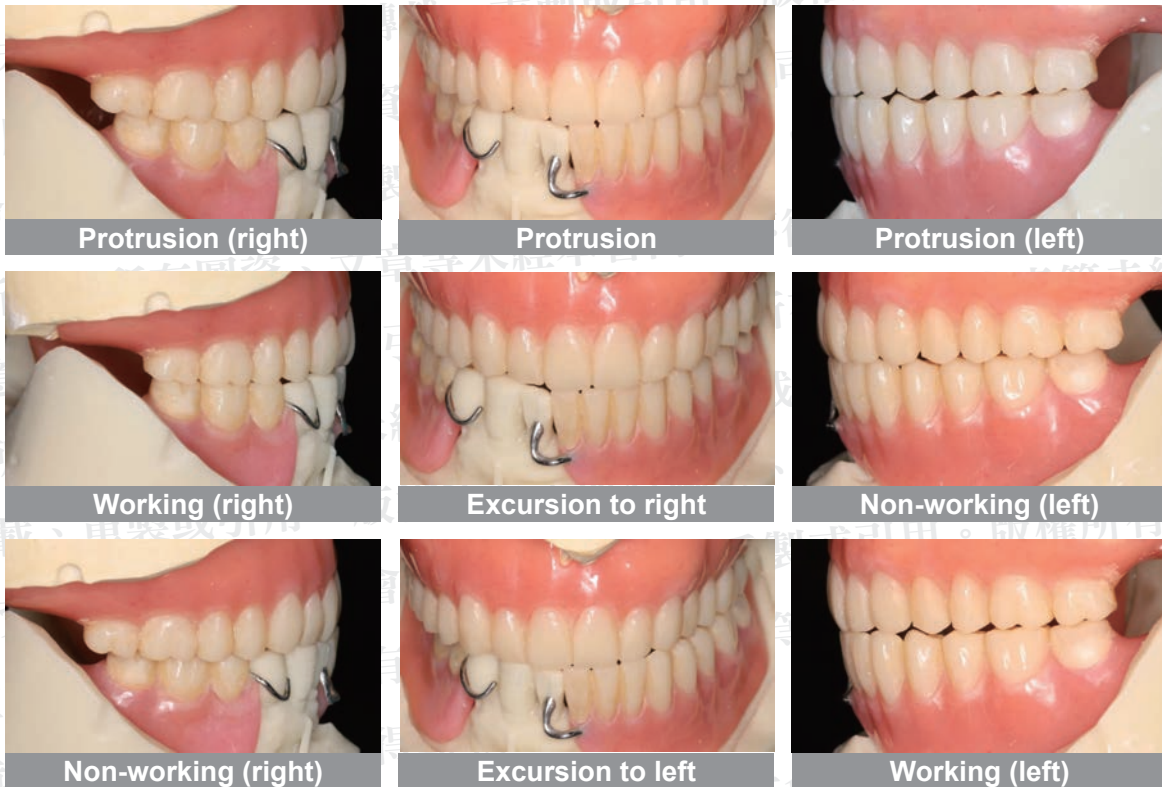
Completed Denture



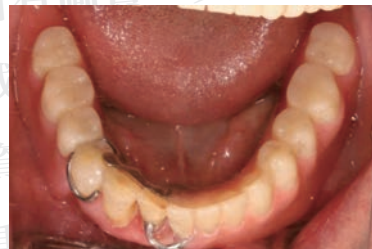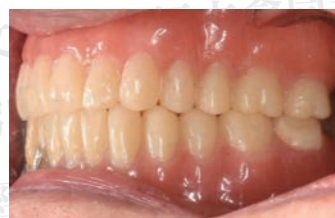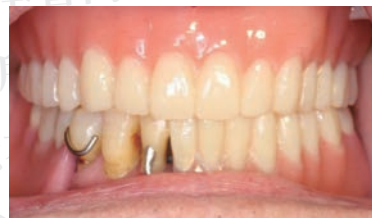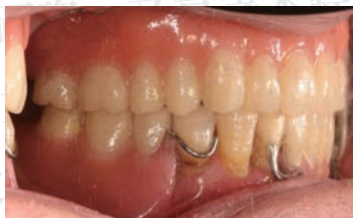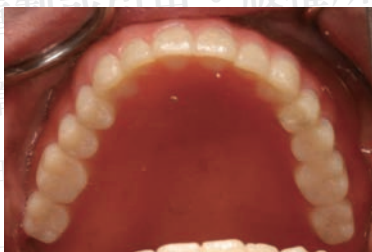*Lower cast was destroyed during Lucitone packing

Eccentric movement

Fully balanced occlusion

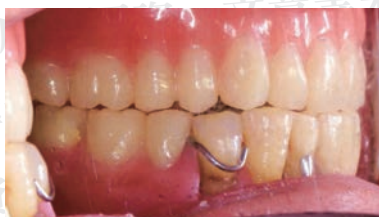

Intra-oral

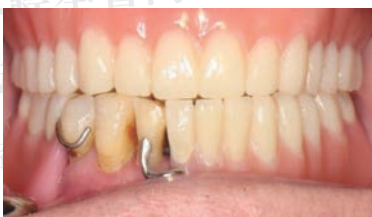

Eccentric movement

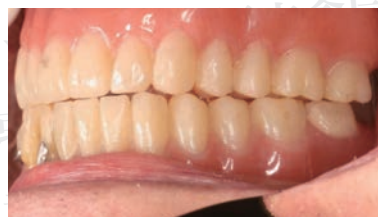Fully balanced occlusion



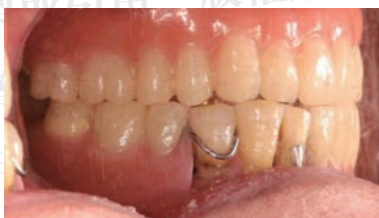Protrusion (right)



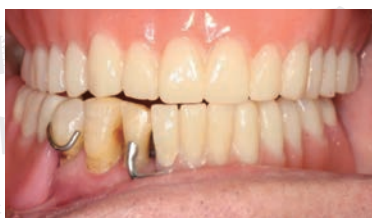Protrusion



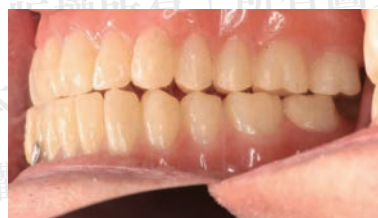Protrusion (left)



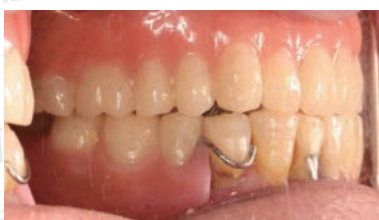Working (right)



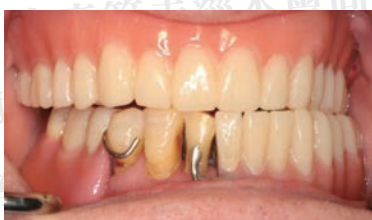Excursion to right



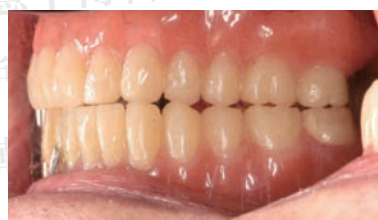Non-working (left)



Non-working (right)

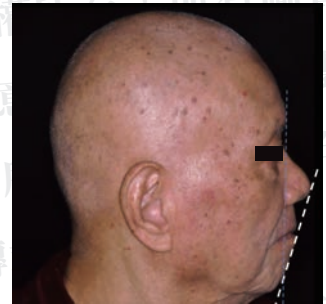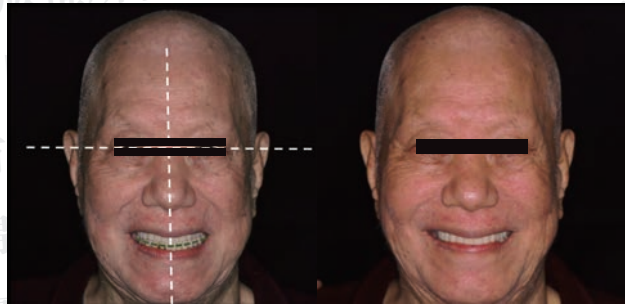
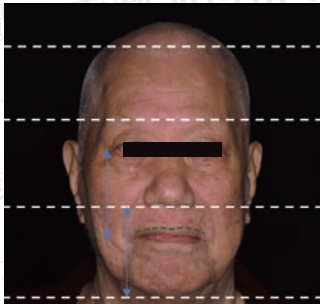


Excursion to left



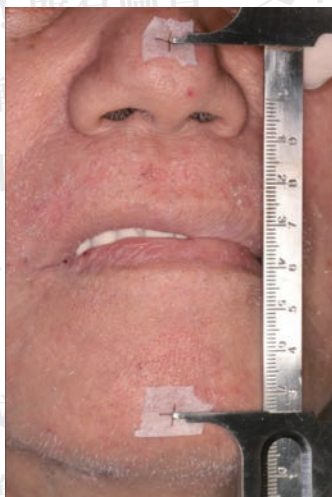Working (left)

Extra-oral

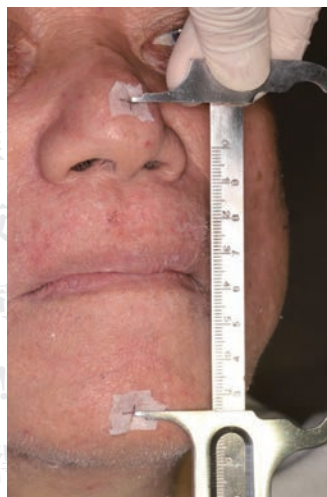

- Ovoid-shaped face
- Facial proportion = 1 : 1.22 : 1.25
- Canthus-commissure = alar-chin
- Lip support
 - smooth cupid's bow support
 - light vermillion border
- Facial dental midline: Upper: on, lower: on, chin: to Lt
- Average smile line, no gummy smile
- Occlusal plane: // lower lip Rt depressor labii inferioris corrected
- Profile: Straight
- Upper/lower lip to E line: U mild retruded, L on
- Lip support
 - Nasolabial angle: $>90^\circ$, decreased
 - Philtrum: shallow concave

Verification of vertical dimension



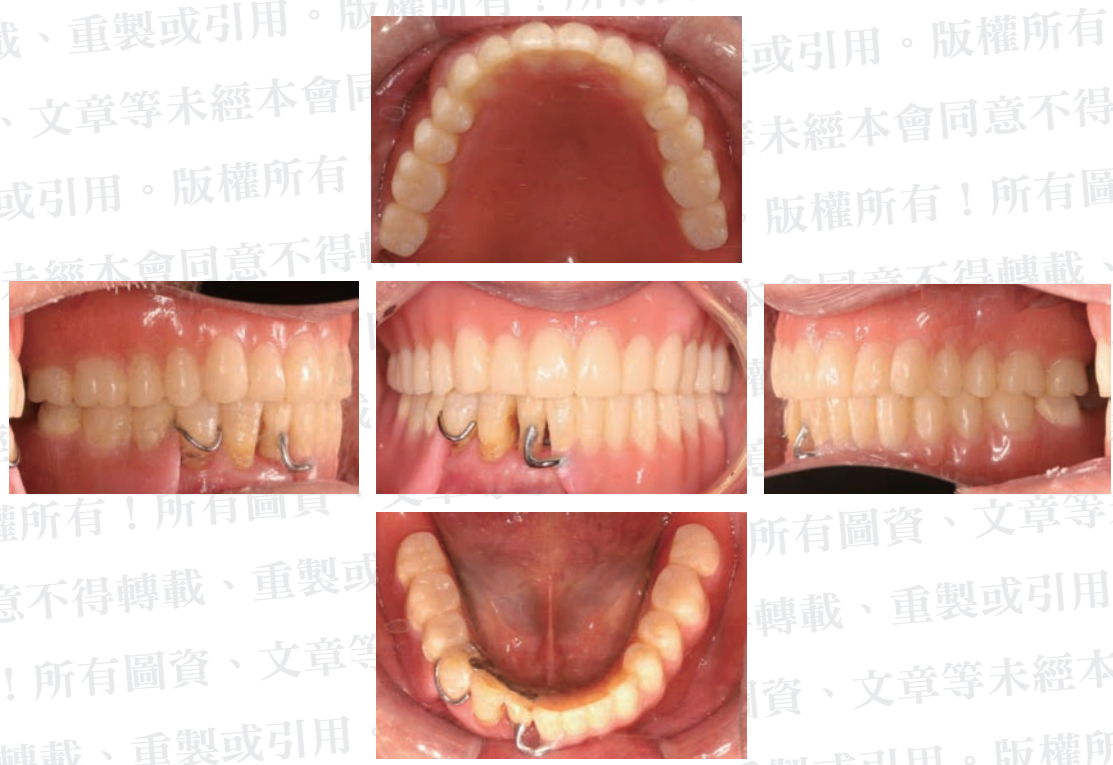Trial denture= 86.9 mm



Final denture= 87.0 mm

	Upper	Lower	Frontal	Smile	Lateral
Initial					
Trial					
Definitive					

6M f/u Intra-oral



Q & A

Q: Trial denture 可以讓病人帶回去？

A: 當初只是用於確認排牙的咬合，但帶回去可以幫忙確認吞咽和 VD；下顎要額外加鉤子

Q: Framework 在數位檔的 relief 如何設計？

A: (楊醫師) 要把 block out 的表面當作組織面，才有空間讓樹脂貼附

Q: Packing error 和 reline 到 framework 的 error 差異？

A: 還需要從更多文獻探究實際上的誤差

Q: Trial denture 重複了很多次，可否簡化？ Gothic arch 做完又 check bite 怎麼取得正確 CR？ Reline packing 在定位上面是不是有困難？如何定位？

A: 第一次是為了試排，第二次是換成主模及重新取得的 Bite，因此會有兩次，也希望排牙都照著數位的模擬去設計，因此不選擇在 framework 上去排牙，但就會面臨後面 reline 定位的問題。Reline 是在主模上用 lucitone 去灌注，誤差在臨床上表現沒有很顯著。

Gothic arch 是因為失智的情況變嚴重才臨時改用新的咬合紀錄方式，若是初期就用這個方式取得，應該也會讓第一次的 Trial denture 準確度更高；而 check bite 則只是想用來確認其和模型上的關係一致而多做的確認，不過對於失智患者很可能這樣的確認會受到排牙的導引。

Q: VD 對於有吞嚥障礙的失智患者是不是不要設計這麼高？

A: 當初設計是以臉部比例去做參考，但如果剛好病人有吞嚥上的障礙，確實需要再多一些考量去決定 VD。

(黃醫師) 在臨床上失智患者沒有特別去減少他的 VD，但對於頭頸癌的病人因為舌壓較低的關係需要減少 VD，但減少的量目前沒有一個確切值。

Q: Dementia 程度和分級與假牙設計關係？ I bar 的設計原因？ 骨頭外型 and 數位的極限？

A: 盡量減少設計的複雜度讓口腔衛生較容易維持，每次都會檢察照護的情況。I bar 長度應長一點從 vestibule 上來會比較有彈性。

骨頭應該要在 pre-prosthetic phase 先進行 alveoloplasty 來減少 undercut，但由於家屬不希望多做手術因此只能留下來。

(楊醫師) 可以從數位模型的 survey 來做評估。




心得

陳建豪

回顧當時在還沒有很多全口活動假牙的經驗時，學長蕭醫師突然決定要讓我挑戰以數位的方式輔助製作，不免感到既緊張又期待。由於之前沒有接觸數位製作活動假牙的病例，因此經歷了很多失敗的嘗試，像是以手機的臉掃 app 結合自製的 reference marker 試圖當作數位面弓時，在技師端發現無法疊合；另外因為病人的 dementia 問題時好時壞，讓每次取得的顎間關係都不一致，因此在排牙的 trial denture 也重來了好多次，和技工所溝通設計的過程更是相當耗時。原本希望以數位的方式簡化流程的心意，反而讓病人多來了很多次，每次也花了更多的時間，增長為兩倍的療程，是在學習過程的代價。

好在完成之後，即便未來假牙有需要重做，有了數位化的紀錄就可以安心地簡化未來的流程，還是會覺得之前的努力沒有枉費吧。感謝學長願意提攜我冒險勇敢嘗試，也謝謝科內主治醫師們在精簡流程上的指教，希望未來能在數位製程上更 smart and smooth 給病人 smile。



陳建豪 醫師

- ◆ 臺北醫學大學學士
- ◆ 林口長庚紀念醫院廣復補綴科受訓醫師